

Alt üriner sistem semptomları ile tarafımıza başvuran hastadaki mesane leiomyomunun başarılı rezeksiyonu: Olgu Sunumu

Case Report: Successful resection of a bladder leiomyoma causing lower urinary tract symptoms

Yavuz Onur Danacıoğlu¹, Bülent Erol¹, Pınar Engin Zerk², Berrin Güçlüer², Asif Yıldırım¹, Turhan Çaçkurlu¹

¹Medeniyet Üniversitesi Göztepe Eğitim ve Araştırma Hastanesi, Üroloji, İstanbul, Türkiye

²Medeniyet Üniversitesi Göztepe Eğitim ve Araştırma Hastanesi, Patoloji, İstanbul, Türkiye

Geliş tarihi (Submitted): 16.09.2017

Kabul tarihi (Accepted): 06.11.2017

Yazışma / Correspondence

Dr. Yavuz Onur Danacıoğlu

İstanbul Medeniyet Üniversitesi Göztepe

Eğitim ve Araştırma Hastanesi, Üroloji

Kliniği, Doktor Erkin Cad. 34722

Kadıköy / İstanbul, Türkiye

Tel: 0216 570 91 65

E-mail: dr_yonur@hotmail.com

Özet

Benign mesenchymal bir tümör olan leiomyomlar en sık uterusun içinde bulunur ve düz kas hücrelerinin bulunduğu her doku ve organda saptanabilmektedir (1). Literatürde mesanede gözlenen leiomyom nadirdir. Mesane leiomyomunun radyolojik bulguları malign lezyonlara benzediği için tanı genellikle cerrahi eksizyondan sonra yapılan histopatolojik tanı ile konulmaktadır. Bu olgu sunumunda 45 yaşında kliniğimize sık idrara çıkma ve idrarda yanma şikayetleri ile başvuran ve açık mesane operasyonu ile lezyonu tamamen çıkarılarak tedavi edilen bir kadın hastayı sunacağız.

Anahtar Kelimeler: mesane, leiomyom, alt üriner sistem semptomları

Abstract

Benign mesenchymal tumors known as leiomyomas are commonly found in the uterus and may also be present in any smooth muscle organ (1). Bladder leiomyomas are rare and mimic malignant lesions on radiological studies hence, surgical excision and histopathological examination are necessary for identification. In this case study, we will be presenting a 45 year old female patient who frequently presents to our clinic with dysuria symptoms who was treated with open bladder excision.

Keywords: bladder, leiomyoma, lower urinary tract symptoms

INTRODUCTION

Benign mesenchymal tumors of the bladder are relatively rare (1). Leiomyoma is the most common benign bladder tumour (35%), but leiomyomas account for less than 0.43% of all bladder tumors (2). They commonly present in the fourth to fifth decade of life (1). The patients who have urinary bladder leiomyoma are mostly asymptomatic but they are rarely presenting urinary voiding complaints such as irritation and obstruction. Diagnosis of such tumors is primarily based on clinical history, physical examination, and imaging techniques. We presented and discussed the history, clinical features, treatment and outcome of our patient who had urinary bladder leiomyoma.

CASE REPORT

A 45 year old premenopausal woman admitted to the outpatient clinic with lower urinary tract symptoms such as frequency, dysuria that had occurred for the previous 4 months. Her medical history was revealed that she had two caesarean deliveries in the past and had history of subcutaneous benign fibrous histiocytoma which was a dermally located mesenchymal tumor. Blood studies including complete blood count and biochemistry were normal. Urine analysis was normal and urine culture was sterile. Her physical examination was unremarkable. Our patient had no contributory medical, family, drug or social history. Pelvic ultrasound was revealed a 25 mm homogeneously hypoechoic, solid mass bottom of the bladder lumen. Contrast-enhanced computed tomography shown that a soft tissue density, polypoid, compression mass was 25x22 mm at the bottom of the bladder.

Tumor has well defined margins. Magnetic resonance imaging (MRI) scan showed a regular shaped 24X23 mm submucosal homogeneously hypointense lesion (T1- and T2-weighted images) in the bottom of the bladder wall with no evidence to extravascular extension with postgadolinium enhancement (Figure 1a and 1b). There was no regional lymphadenopathy or metastatic disease and no compression of the bilateral vesicoureteric junction and no hydronephrosis. A cystoscopy was revealed a 25 mm in diameter intraluminally protruding solid mass with under normal urothelial epithelium at the bladder neck.

Excision biopsy was planned for the next operation and was not taken any biopsies with transurethral resection (TUR). Surgical exploration was undertaken via a Pfannenstiel incision and open local excision was performed with at least a 5-mm margin around the tumor. The size of the specimen was 25x20x15 mm. The diagnosis of leiomyoma was confirmed on histopathology. Grossly the mass measured 17x11x8 mm in greatest dimensions with smooth surface and hard consistency (Figure 2a). Composed of well differentiated smooth muscle that consist of interlacing fascicles of uniform spindle cells with eosinophilic cytoplasm and oval, blunt ended nuclei. Variable degree of degenerative atypia, absent mitotic activity and calcification or ossification may be seen. Typically smooth muscle actin (SMA) is immunopositive (Figure 2b). CD 34 is immunonegative (Figure 2c). The patient was discharged the fifth day after the operation and an 18 french two way Foley's catheter was kept for five days. The patient voided with good flow after catheter removal. Postoperative period was uneventful and the patient has not any complaint.

DISCUSSION

The first bladder leiomyoma was published in 1931 by Kretschmer JL and colleagues (3). The etiology of these tumors still remains unknown. There are many proposed etiologies for leiomyoma arise from chromosomal anomalies, hormonal influences, bladder musculature infection, dysontogenesis or perivascular inflammation (4). Urinary bladder leiomyoma can be presented three kinds of type in location. Endovesical is the most common form, accounting for 63-86% of the cases, followed by extravascular (11-30%), while intramural type is less common accounting for 3-7% of the cases (5). Our patient had an endovesical 25 mm solid lesion and that was located at the bottom of the bladder. It occurs more frequently in females than males (female to male ratio is 3:1) (6). Although it is unknown why leiomyoma is seen more commonly amongst females, it is thought that this increase is due to an effect of estrogen on leiomyoma (7). Leiomyoma occurs rarely on the prepubertal cases. It mostly occurs between ages of 30 and 40 therefore female hormones affect most actively (8). Urinary bladder leiomyomas are mostly asymptomatic or may present with

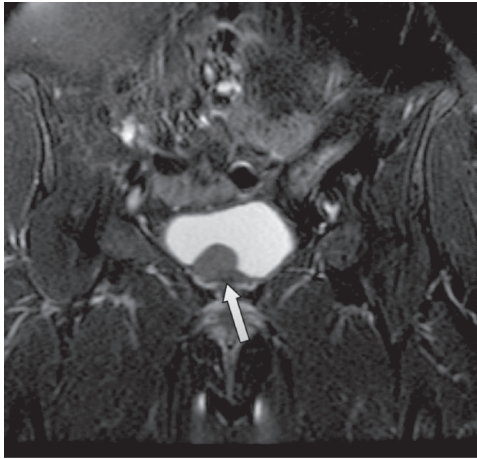


Figure 1a

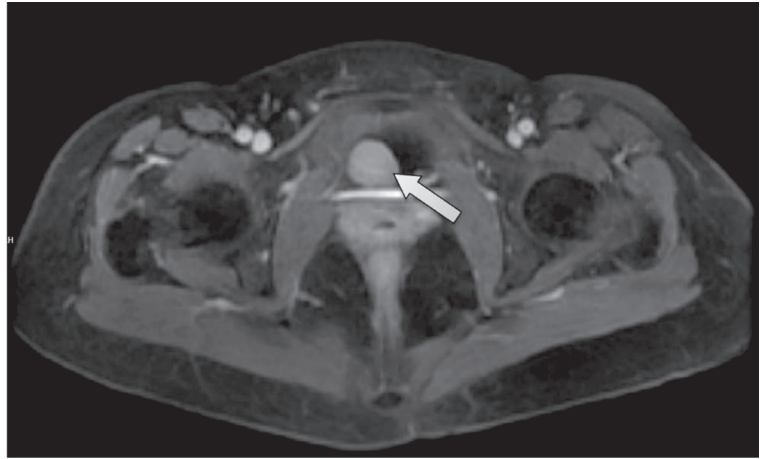


Figure 1b

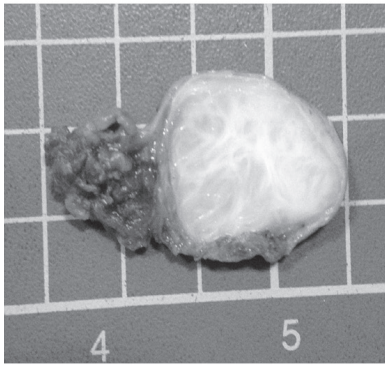


Figure 2a

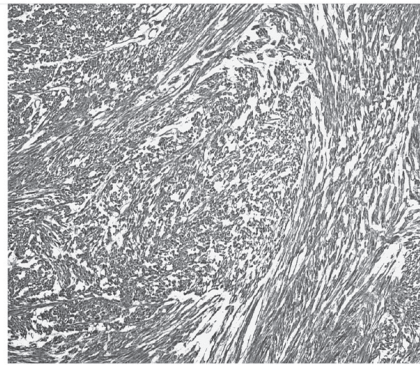


Figure 2b

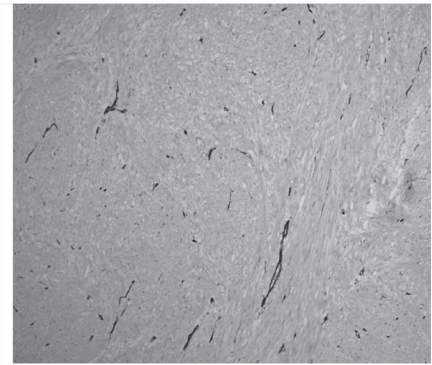


Figure 2c

obstructive and irritative LUTS or gross hematuria. In a review of 37 cases by Goluboff et al., obstructive symptoms were most commonly seen (49%) in addition to leiomyoma of bladder rarely causes incontinence. Irritative LUTS were observed in 38% of cases while 11% of cases had hematuria and 19% of cases had no symptoms (4). In a more recent review by Silva-Ramos et al, the result of reviewing 90 cases of leiomyoma in the literature showed that irritative LUTS was most common (50%), obstructive LUTS was present in 24% of cases (9). Symptoms can change depend on the lesion size and location of lesions. Endovesical type usually presents more symptoms because it may protrude into the bladder leading to irritation related complaints. Our patient had a endovesical tumor and presented with similar symptoms.

A thorough physical examination is important and necessary for the diagnosis bladder leiomyoma according to Goluboff et al, a palpable lesion was found in 57% of women who underwent a bimanual examination (4).

A careful physical examination, radiological examination and ureteroscopy are mandatory to recognize it from urethrocele, urethral diverticulum and caruncle. Also USG (ultrasonography), CT (computed tomography), MRI (magnetic resonance imaging) and cystoscopy are beneficial diagnostic tools that can describe the morphology and anatomic location of the bladder leiomyoma (10). Our patient presented with lower urinary tract symptom, her physical examination did not reveal any particular findings and the lesion was determined by the initial imaging procedure which is transabdominal ultrasound. On the other hand MRI is considered superior to CT scan since it provides better soft-tissue contrast and resolution (Figure 1a and 1b). MRI of the bladder can distinguish mesenchymal tumors from the more common transitional cell tumors (11). At MRI, the normal bladder wall is of intermediate signal intensity on the T1-weighted image while there is an intermediate to low signal intensity on T2-weighted images. On MRI, nondegenerative leiomyo-

mas are usually visualized as low-intensity nodules both on T1 and T2 weighted sequences with a smooth surface while degenerative leiomyomas have a heterogenous signal intensity on contrast enhanced MRI (10). In our case MRI revealed a regular shaped mass arising bottom of the bladder, presented hypointense signal on T1 and T2 weighted image. The final diagnosis should be obtained by the histopathological examination. Surgical removal is the primary treatment for urinary bladder leiomyoma. Goluboff et al reported that 62% were treated by open resection while 30% were removed transurethral resection (4). In our case, the tumor was successfully removed by open surgical resection which was located in the bottom of bladder. Bladder leiomyomas can be directly distinguished from leiomyosarcoma by the histopathological examination. The bladder leiomyomas are benign tumors, surgical resection is therapeutic and malignant degeneration of leiomyoma is not clinically observed (7).

CONCLUSION

Benign leiomyomas can't be easily differentiated from malignant lesions with conventional diagnostic methods and cystoscopic evaluations. Surgical intervention is the best choice to establish of the diagnosis and this approach is clinically sufficient for treatment and for assignment of prognosis.

REFERENCES

1. Soloway D, Simon MA, Milikowski C, Soloway MS. Epithelioid leiomyoma of the bladder: an unusual cause of voiding symptoms. *Urology* 1998; 51: 1037-9.
2. Campbell EW, Gislason GJ. Benign mesothelial tumors of the urinary bladder: review of literature and a report of a case of leiomyoma. *J Urol* 1953; 70: 733-41.
3. Kretschmer JL. Leiomyoma of the bladder with a report of a case and a review of the literature. *J Urol* 1931; 26: 575-89.
4. Goluboff ET, O'Toole K, Sawczuk IS. Leiomyoma of bladder: report of case and review of literature. *Urology* 1994; 43: 238-41.
5. Singh O, Gupta SS, Hastir A. Laparoscopic enucleation of leiomyoma of the urinary bladder: a case report and review of the literature. *Urol J* 2011; 8: 155-8.
6. Mooppan MM, Kim H, Wax SH. Leiomyoma of the female urethra. *J Urol* 1979; 121: 371-2.
7. Kim IY, Sadeghi F, Slawin KM. Dyspareunia: an unusual

- presentation of leiomyoma of the bladder. *Rev Urol* 2001; 3: 152-4.
8. Bai SW, Jung HJ, Jeon MJ, et al. Leiomyomas of the female urethra and bladder: a report of five cases and review of the literature. *Int Urogynecol J* 2007; 18: 913-7.
 9. Silva-Ramos M, Masso P, Versos R, Soares J, Pimenta A. Leiomyoma of the bladder. Analysis of a collection of 90 cases. *Actas Urol Esp* 2003; 27: 581-6.
 10. Fasih N, Prasad Shanbhogue AK, Macdonald DB, et al. Leiomyomas beyond the uterus: unusual locations, rare manifestations. *Radiographics* 2008; 28: 1931-48.
 11. Sundaram CP, Rawal A, Saltzman B. Characteristics of bladder leiomyoma as noted on magnetic resonance imaging. *Urology* 1998; 52: 1142-3.