

Chylous ascites after laparoscopic donor nephrectomy: First case report in Turkey

Laparoskopik donör nefrektomi sonrasında şilöz asit: Türkiye'deki ilk olgu sunumu

Selcuk Sahin¹, Osman Ozdemir¹, Ismail Evren¹, Serdar Karadag¹, Volkan Tugcu², Ali Ihsan Tasci¹

1 Bakirkoy Dr. Sadi Konuk Training and Research Hospital, Department of Urology, Istanbul, Turkey

2 Memorial Bahcelievler Hospital, Department of Urology, Istanbul, Turkey



Submitted: 2020-06-01

Accepted: 2020-10-11

Correspondence

Osman Ozdemir

Tevfik Saglam Cd. No:1, 34147

Bakirkoy, Istanbul / Turkey

e-mail: ozdemirosmann2@gmail.com

T: +90 505 707 03 08

ORCID

S.S. 0000-0002-0903-320X

O.O. 0000-0003-0375-8282

I.E. 0000-0003-4008-8038

S.K. 0000-0002-1420-4536

V.T. 0000-0002-4136-7584

A.I.T. 0000-0002-6943-6676



This work is licensed under a [Creative Commons Attribution-NonCommercial 4.0 International License](https://creativecommons.org/licenses/by-nc/4.0/).

Özet

Son dönem böbrek yetmezliğinin tedavilerinden biri canlı verici böbrek naklidir. Birçok nakil merkezinde, laparoskopik canlı donör nefrektomi standart yaklaşım olarak uygulanmaktadır. Şilöz asit, laparoskopik donör nefrektomi (LDN) sonrası çok nadir görülen bir komplikasyondur. Türkiye'deki donör nefrektomi sonrası ilk şilöz asit vakasının yönetimini sunmayı amaçladık. 62 yaşında erkek hastaya laparoskopik transperitoneal sol donör nefrektomi yapıldı. Taburcu olduktan bir ay sonra batında distansiyon ile başvuran hastaya yapılan görüntülemelerde batında yaygın serbest sıvı saptandı. Perkütan drenaj kateteri takılan hastada drenaj kateterine gelen sıvının süt renginde, şilöz vasıfta olduğu görüldü. Hasta perkütan drenaj, somatostatin analogu ve total parenteral nutrisyon kombinasyonu ile tedavi edildi.

Anahtar Kelimeler: şilöz asit; laparoskopik donör nefrektomi; komplikasyon

Abstract

Living-donor kidney transplantation is one of the treatment options of end-stage renal failure. In many transplant centers, laparoscopic live-donor transplantation is recognised as the standard procedure. Chylous ascites (CA) is a very rare complication after laparoscopic donor nephrectomy (LDN). We aimed to present the management of the first case report in Turkey. 62-year-old male patient underwent laparoscopic transperitoneal left donor nephrectomy. One month after discharge, he was admitted with abdominal distention and imaging revealed diffuse free fluid in the abdomen. After diagnosis, milky colored chylous fluid was collected by inserting a percutaneous drainage catheter. The patient was treated with combination of percutaneous drainage, somatostatin analogue and total parenteral nutrition.

Keywords: chylous ascites; laparoscopic donor nephrectomy; complication

INTRODUCTION

Living-donor kidney transplantation is the treatment of end-stage renal failure. Donor nephrectomy operations can be done with open, laparoscopic or robotic surgery and with the spread of minimally invasive approaches laparoscopic live donor nephrectomy has become the standard approach in many transplant centers due to its advantages, such as shorter recovery time and reduced postoperative pain (1, 2).

In laparoscopic donor nephrectomy (LDN), it is necessary to minimize the risks for the donor, to be careful about the complications and to ensure the safety of the donor (3). Complication rates after laparoscopic donor nephrectomy vary from 6.4% to 16.5% (4). Chylous ascites (CA), which usually occurs after abdominal aortic surgery, is a complication due to the incision of lymphatic vessels during operation and leakage of the fluid in these lymphatic vessels. CA is very rare after LDN and has been reported in the literature between 0.07% and 5.9% of cases. (2, 4, 5, 6).

There is no published case of CA after LDN in our country. We aimed to present the management of our case who developed CA in the light of literature.

Case Report

A 62-year-old male patient underwent a laparoscopic transperitoneal left donor nephrectomy and was discharged on the postoperative second day without any perioperative complication. One month after

discharge, he was admitted with abdominal distention. The patient did not have any other symptoms like fever or pain. Physical examination revealed severe abdominal distention but defense and rebound was not detected. In the laboratory tests, serum creatinin level and white blood cell count were normal. A computed tomography (CT) scan was performed and diffuse free fluid was observed in the abdomen (Figure 1, 2). After diagnosis, percutaneous drainage catheter was inserted and 3000 ml milky colored chylous fluid was removed (Figure 3). Laboratory tests of the fluid revealed that the triglyceride level was 1760 mg/dl and the culture was sterile. Simultaneously with drainage catheter insertion, oral intake was stopped and total parenteral nutrition (TPN) and octreotide (0.1 mg, 3 times/day) were started. In the daily follow-up of the drainage catheter, a total of 14000 cc was delivered in the first 24 hours and 5000 cc in the second 24 hours. In the following days, it was observed that the amount of drain decreased regularly. The patient was followed up for three weeks while he was kept nil by mouth and received TPN. After that a low-fat diet was started. The drainage catheter was removed on the 27th day when it was dry even after starting diet. The patient was treated with combination of percutaneous drainage, somatostatin analogue and TPN. There was no requirement for an additional surgical operation. No pathology was detected at the patient's one-year follow-up after the procedure.

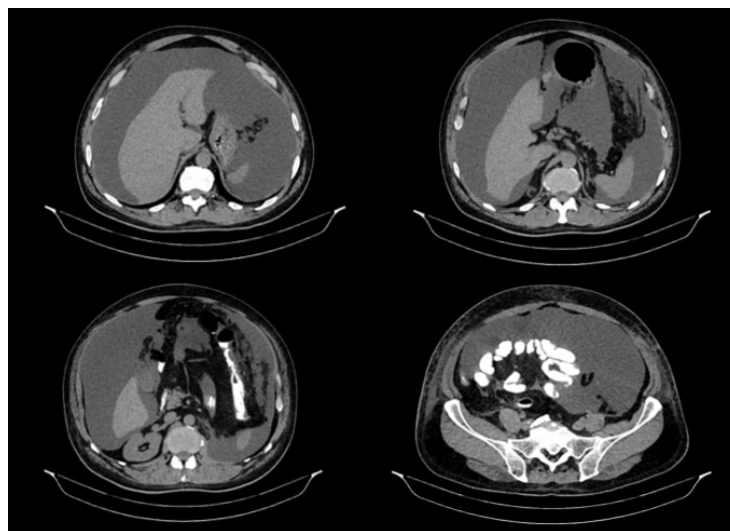


Figure 1: CT image of diffuse intraabdominal fluid at various levels in transverse section.

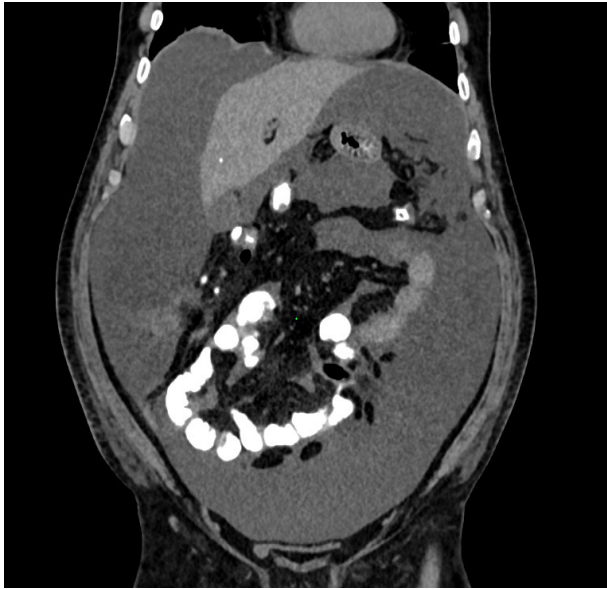


Figure 2. CT image of diffuse intraabdominal fluid in coronal section.

DISCUSSION

Laparoscopic donor nephrectomy (LDN) is the standard of care in many transplant centers. It has been reported that donors undergoing laparoscopic surgery experience reduced postoperative pain and faster recovery of function(7). Donor nephrectomy surgeries are applied to healthy individuals, therefore it is important to be careful about complications and one of the complications encountered in LDN is CA.

CA, which usually occurs after abdominal aortic surgery is a rare complication and can cause serious metabolic disorders and high morbidity (6, 8). It is thought that chylous ascites develops due to injury of lymphatic vessels in the paraaortic region during dissection of renal vessels. The paralumbar lymphatic truncus carrying lymph from the lower extremities, genitals and pelvic organs joins with intestinal truncus and form the cisterna chyli in the paraaortic region. Especially during left donor nephrectomy, renal arter should be dissected near the aorta in order to obtain sufficient length, however, that can cause damage to these lymphatic structures and development of CA.

Various algorithms are presented in the literature for management of CA, but there is no consensus (8, 10). The first step of treatment is the conservative ap-

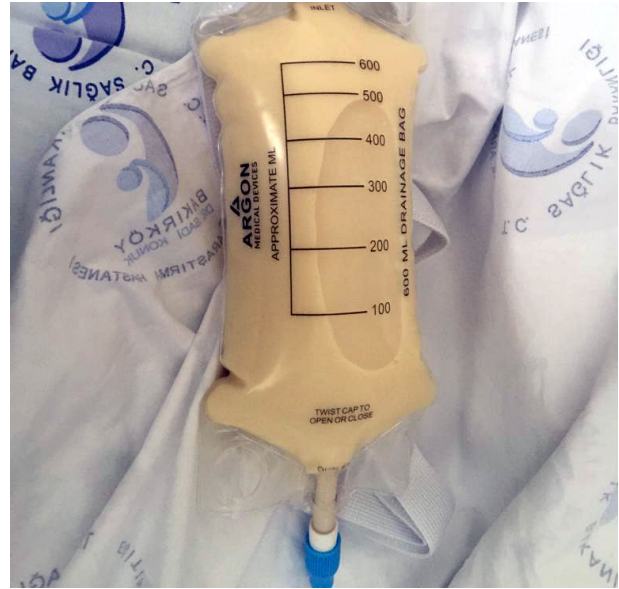

Figure 3. Milky colored chylous fluid in the drainage bag.

proach whose aim is to reduce mesenteric lymphatic flow. Dietary modification is one of the most important aspects of the conservative treatment and it is thought that low fat diet reduces lymphatic flow and closes the leakage over time. In addition, somatostatin and somatostatin analogs have also been reported to reduce intestinal fat absorption and lymphatic flow. Octreotide is recommended as a part of the conservative treatment, but it is not clearly identified how long the treatment will continue (2, 8). TPN treatment is also offered as a conservative approach. In the article published by Dale et al, TPN was indicated as the first-line treatment with dietary modifications, while Tiong et al. reported that as a second-line treatment if diet manipulations are insufficient (5, 6).

It has been stated in various publications that the conservative treatment can be applied for 4 to 12 weeks (2, 6, 8). Side effects such as malnutrition, immunodeficiency, electrolyte imbalance may develop due to the conservative treatment and it can also causes high medical expenses and psychological distress on the patient due to prolonged hospitalization (2, 5). The conservative approach has been reported to fail in approximately 24-40% of patients and this patients may require more invasive treatment methods such as para-

centesis, intraabdominal drain placement or surgical exploration (5, 10).

Paracentesis can be used for both diagnosis and treatment when patients present with abdominal distention and compression symptoms. It has been stated that percutaneous drainage catheters are often required but drainage should always be applied together with the conservative measures. The timing and role of surgical treatment in CA treatment is still controversial. Leakages over 1000 cc per day have been reported to be considered for surgical treatment (10).

When the literature is examined, it is seen that there is no consensus for the treatment of CA. Therefore, Ng et al presented a classification system and treatment strategy. They classified leaks less than 300 ml as mild, those between 300-800 ml as medium and more than 800 ml as serious chyle leak. They stated that no intervention is required for mild to moderate leaks, and they recommended dietary modifications and treatment with subcutaneous octreotide 3 times a day. For severe leakage, it is stated that the oral intake should be closed and TPN is recommended, and the drain placed in these patients should not be removed until it is completely dry. He suggested that surgical treatment should be evaluated according to the early response, but he recommended surgery to the patient who had no response to the treatment for 2 weeks (2).

Jairath et al published an article in which 1156 laparoscopic nephrectomy cases were examined and 9 cases of CA were reported. They also reported that 3 of these 9 CA cases required surgical exploration and they described a management protocol for CA. According to this protocol, conservative treatment is recommended for chylous leaks up to 1000 cc/per day, while laparoscopic exploration is recommended in cases with more than 1000 cc/per day for more than 48 hours (10). In our case, contrary to this protocol, although daily leakage was above 1000 cc, surgical treatment was not performed but a successful result was achieved.

Dale et al reported that the conservative approach had various side effects and suggested intraabdominal drain placement as a first-line treatment, contrary to the common belief in the literature. They reported

that surgical treatment may not be necessary even in patients with leakage of more than 1000 ml per day, the percutaneous drain is safer and they opposes Jairath's algorithm (5, 10). Also in our case the drained fluid was measured 14000 ml on the first day and 5000 ml on the second day but the surgery did not performed and the patient was treated with the conservative measures in addition to percutaneous drainage and our case supports Dale's report.

The primary goal should be preventing lymphatic leakage in order to avoid chylous ascites which is a difficult complication to manage. It has been reported that electrocautery may not be sufficient to control lymphatics in the paraaortic region, and the usage of clips during dissection in this area may prevent this complication before it occurs (6). In our cases following this complication, clips were used for lymphatics at the dissection site to prevent CA.

CONCLUSION

In conclusion, CA is a very rare complication after LDN. Although there is not a standard practice for the treatment of CA, successful results can be achieved by the combination of intraabdominal drainage catheter placement and the application of the conservative measures.

Acknowledgement

No acknowledgments to declare.

Conflict of Interest

All authors declared that there is no conflict of interest.

Financial Disclosure

The authors declared that this study has received no financial support.

REFERENCES

1. Ratner LE, Ciseck LJ, Moore RG et al. Laparoscopic live donor nephrectomy. *Transplantation*. 1995; 60(9):1047-1049.
2. Ng ZQ, He B. A Proposed Classification System and Therapeutic Strategy for Chyle Leak After Laparoscopic Living-Donor Nephrectomy: A Single-Center Experience and Review of the Literature. *Exp Clin Transplant*. 2018 ;16(2):143-149.

3. Janki S, Dor FJ, IJzermans JN. Surgical aspects of live kidney donation: an updated review. *Front Biosci (Elite Ed)*. 2015; 7:394–416.
4. Breda A, Veale J, Liao J, Schulam PG. Complications of laparoscopic living donor nephrectomy and their management: the UCLA experience. *Urology*. 2007; 69(1):49-52.
5. Dale L-A, Sandoval PR, Ratner LE. Chylous ascites following laparoscopic live donor nephrectomy: A new improved treatment paradigm. *Clin Transplant*. 2019; 33:13483.
6. Tiong HY, Goel RK, White WM, Goldfarb DA, Kaouk JH. Chylous ascites after laparoscopic donor nephrectomy. *Asian J Endosc Surg*. 2015; 8(1):34-39.
7. Ratner LE, Montgomery RA, Kavoussi LR. Laparoscopic live donor nephrectomy. A review of the first 5 years. *Urol Clin North Am*. 2001; 28(4):709-719.
8. Leibovitch I, Mor Y, Golomb J, Ramon J. The diagnosis and management of postoperative chylous ascites. *J Urol*. 2002; 167:449-457.
9. Meulen ST, van Donselaar-van der Pant KA, Bemelman FJ, Idu MM. Chylous ascites after laparoscopic hand-assisted donor nephrectomy: Is it specific for the left-side?. *Urol Ann*. 2013; 5(1):45-46.
10. Jairath A, Singh A, Ganpule A et al. Management Protocol for Chylous Ascites After Laparoscopic Nephrectomy. *Urology*. 2015; 86(3):521-528.