

Cinsel memnuniyet amacıyla penil cilt altına tesbih boncuğu yerleştirilmesi: Nadir bir olgu sunumu

*Implantation of prayer beads beneath the penile skin for sexual pleasure:
A rare case report*

Fatih Akdemir¹, Önder Kayıgil², Emrah Okulu³

¹ Samsun Terme Devlet Hastanesi Üroloji Uzmanı, Samsun, Türkiye

² Yıldırım Beyazıt Üniversitesi Tıp Fakültesi, Üroloji Ana Bilim Dalı, Ankara, Türkiye

³ Ankara Atatürk Eğitim ve Araştırma Hastanesi, Üroloji Kliniği, Ankara, Türkiye

Geliş tarihi (Submitted): 09.10.2016

Kabul tarihi (Accepted): 16.01.2017

Yazışma / Correspondence

Fatih Akdemir

Gölevi Mahallesi, Toki Sokak, No:

11/21, Ünye, Ordu, Türkiye

Phone: 0538 404 0494

E-mail: nfatihakdemir@hotmail.com

Özet

Seksüel performansı, partner zevkini veya penil estetiği artırmak amacıyla penis cildi altına mermerler, rulman, yağlar, modifiye ev eşyaları, parafin, mineral yağı, vazelin ve silikon gibi yabancı cisim yerleştirilmesi yapıldığı raporlanmıştır. Penise yabancı cisim yerleştirilmesi tıbbi bilgisi olmayan kişilerce yapılmakta olup sonuçta enfeksiyon gelişimine yatkınlık oluşturduğu ve çıkartılması gerektiği bilinmelidir. Biz, tesbih boncukları partneri tarafından penis cildi altına yerleştirilen 31 yaşındaki olguyu literatür bilgileri eşliğinde irdledik.

Anahtar Kelimeler: Penis, yabancı cisim, tesbih boncuğu

Abstract

In addition to different substances such as mineral oil, paraffin, vaseline and silicon, a variety of foreign bodies such as marble, ball bearings and pearls have been reported to be placed beneath the skin of the penis shaft to increase sexual performance, partner satisfaction and penile aesthetics. Since this sort of implantation is generally performed by people with no medical knowledge, there is an increased risk of infection, and these objects should be removed. Following a review of the literature, we evaluated a 31-year-old patient in whom prayer beads had been implanted beneath the penile skin by his partner.

Keywords: Penile, foreign body, rosary beads

INTRODUCTION

Foreign bodies being implanted beneath the skin of the penis shaft in order to increase sexual pleasure and the orgasmic response of the partner is a practice mostly adopted by people from a low socioeconomic background or prisoners.^[1] Since these procedures are mostly performed under non-sterile conditions by unqualified people, they often result in the development of infections. In the literature, there are reports on the implantation of beads; however, to the best of our knowledge, this is the first case in whom prayer beads were used to improve the sexual satisfaction of the partner

CASE REPORT

A 31-year-old male was referred to our clinic requesting the removal of foreign bodies that had been implanted beneath his penis skin one year previously in order to enhance his partner's sexual pleasure and increase penile aesthetics. The history of the patient revealed that the beads had been implanted beneath the penile skin without local anesthesia and under nonsterile conditions by his partner who worked in a piercing shop. Physical examination revealed visible foreign bodies on the penile shaft and palpation revealed hard substances (Figure 1). After receiving the patient's informed consent and making the necessary preparations, a vertical incision was made under general anesthesia to the dorsal side of the penis to explore the subcutaneous tissue (Figure 2). A total of 19 beads of various sizes were excised from inside the tunica dartos (Figure 3). The beads that were removed were covered by an infected membrane and there was an abscess in a small area. The patient was started on aerobic and anaerobic spectrum antibiotics, and discharged on the second postoperative day without any further problems and instructed to continue the antibiotic treatment for two days.

DISCUSSION

A large phallus has always been a symbol of power in many cultures throughout the history. The implantation of foreign bodies beneath the penile skin is a method used to increase the penile size and enhance sexual pleasure. It has been reported that, in addition to the implan-

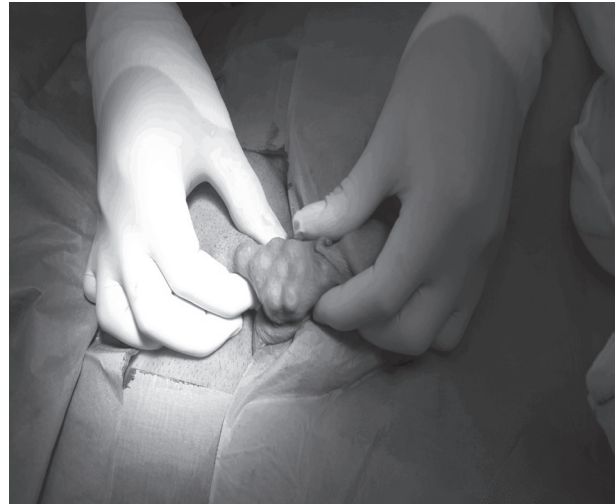


Figure 1: Prayer beads visible beneath the skin of the penis shaft

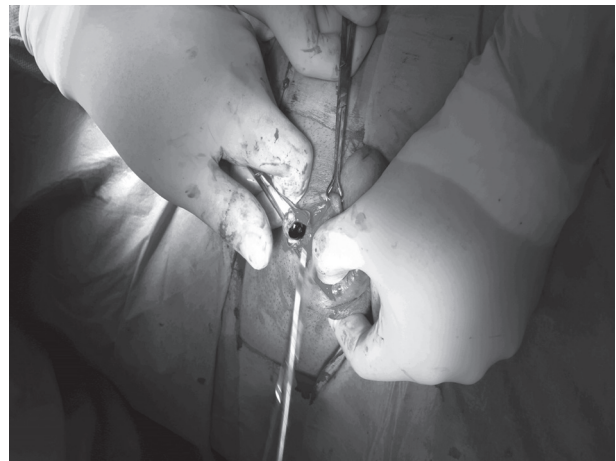

Figure 2: Intraoperative image of the beads

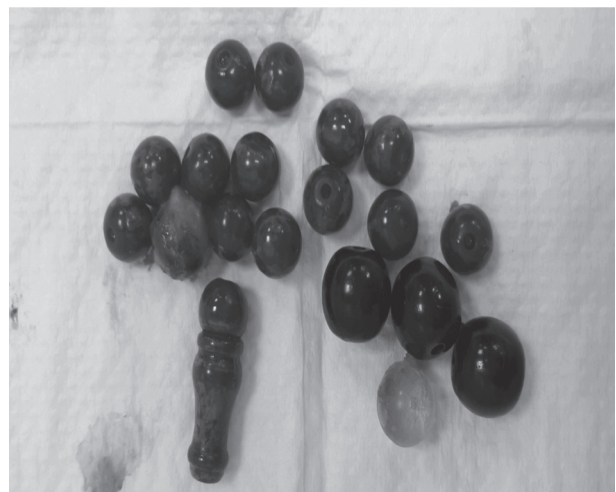

Figure 3: Nineteen prayer beads removed from the patient

tation of chagan balls and various types of beads, various substances such as paraffin, mineral oil and petroleum jelly are injected underneath the penile skin.^[2] The first published report on the implantation of beads underneath the penile skin was in 1953 by Grimaldi.^[3]

Modern case reports reveal the implantation of objects such as rings, elastic bandages, metal nuts, bearings, circumcision apparatus and even hair around the penis to improve sexual satisfaction and duration of erection.^[4] These procedures were mostly performed by people with no medical knowledge under inappropriate conditions.^[2] The procedure is performed by placing one or more beads under the penile skin and the superficial fascia with the aid of sharp or penetrative equipment without local anesthesia. These objects are called artificial penile nodules and they are generally reported to be asymptomatic.^[5] Foreign body implantation results in local complications such as penile lymphogranuloma, infection, ulceration, local irritation and cavernous invasion that may lead to the development of further functional dysfunctions as well as systemic complications such as foreign body embolization, organ infarction and death.^[6]

Marzouk reported the implantation of beads in 60 workers.^[7] These workers were reported to be mentally healthy but were from a lower socioeconomic class. The author found that there were three different reasons behind the adoption of this sexual practice. One group suffered from sexual inferiority complex and thus aimed to improve their penile length. Another group of workers wished to take revenge on the female partner living in their country of origin for having sexual intercourse with other man. They had these beads embedded in order to make coitus painful and prove that they were sexually superior. The last group reported that they had only copied their friends. In the current case, the beads had been implanted by the patient's partner under non-sterile conditions to enhance sexual satisfaction during intercourse.

The practice of implanting foreign bodies beneath the penile skin is mostly adopted by people with a low socio-economic level and performed by people with no medical knowledge. These procedures usually result in the development of infections and therefore it is necessary to remove the implants immediately. In addition, it is of crucial importance to inform the society about the

risks involved in these procedures to prevent communicable diseases and various complications.

REFERENCES

1. Lim KB, Seow CS, Tulip T, Daniel M, Vijayasingham SM. Artificial penile nodules: case reports. *Genitourin Med* 1986;62:123-5.
2. Karakan T, Ersoy E, Hasçıçek M, et al. Injection of Vaseline under Penis Skin for the Purpose of Penis Augmentation. *Case Rep Urol* 2012;19: 510612.
3. Grimaldi AA. Cuerpo extraño de pene: exaltación del orgasmo conyugal mediante el injerto de cuatro perlas. *Rev Argent Urol* 1953;22:271-2.
4. Van Ophoven A, De Kernion JB. Clinical management of foreign bodies of the genitourinary tract. *J Urol* 2000;164:274-87.
5. Nitichandhaprabhas P. Artificial penile nodules: case reports from Thailand. *Br J Urol* 1975;47:463.
6. Inn FX, Imran FH, Ali MF, Rizuana I, Zulkifli Z. Penile augmentation with resultant foreign material granuloma and sequelae. *Malays J Med Sci* 2012;19:81-3.
7. Marzouk E. Implantation of beads into the penile skin and its complications. *Scand J Urol Nephrol* 1990;24:167-9.