

## Methylene blue-guided retroperitoneoscopy technique: alternative for percutaneous nephrolithotomy in cases with renal access failure

Metilen mavisi retroperitonoskopi tekniği: renal akses sağlanamayan perkütan nefrolitotomi vakalarında alternatif

Serdar Karadağ, Mithat Ekşi

University of Health Sciences, Bakırköy Dr. Sadi Konuk Training and Research Hospital, Department of Urology, Istanbul, Turkey



Geliş tarihi (Submitted): 2022-05-10

Kabul tarihi (Accepted): 2022-10-12

### Yazışma / Correspondence

Mithat Ekşi

Zuhuratbaba, Dr. Tevfik Sağlam Cd  
No:11, Bakırköy Dr.Sadi Konuk Hospital,  
Department of Urology,  
34147, İstanbul / Türkiye  
E-mail: mithat\_eksi@hotmail.com  
Tel: +90 506 252 82 83

### ORCID

S.K. 0000-0002-1420-4536

M.E. 0000-0003-1490-3756



This work is licensed under a [Creative Commons Attribution-NonCommercial 4.0 International License](https://creativecommons.org/licenses/by-nc/4.0/).

### Özet

**Amaç:** Perkütan Nefrolitotomi cerrahisinde (PNL) çeşitli sebeplerle ekstrasvazyon gelişen ve neticesinde komplike olan vakalarda uyguladığımız ‘Metilen Mavisi Eşliğinde Retroperitonoskopi Tekniği’ni sunmak.

**Gereç ve Yöntemler:** 2014-2020 yılları arasında Bakırköy Dr. Sadi Konuk SUAM’da ‘Metilen Mavisi Tekniği’ uygulanarak yapılan 36 PNL vakası retrospektif olarak değerlendirildi. Renal skar ya da tüm kaliksi dolduran staghorn kalkül sebebiyle Amplatz kılıfının ilerletilemediği, Amplatz kılıfın yardımcı ekip tarafından dikkatsizlik sonucunda rehber tel ile birlikte çekildiği ve ekstrasvazyon gelişen durumlarda “Metilen Mavisi” yöntemi kullanılan olgular çalışmaya dahil edildi. Hastalara ait demografik, preoperatif, perioperatif ve postoperatif verileri kaydedildi, taşsızlık ve komplikasyon oranları belirtildi.

**Bulgular:** Hastaların ortalama yaşı 45,1 yıl (36-55), ortalama vücut kitle indeksi  $27,8 \pm 4$  kg/m<sup>2</sup>, ortalama taş boyutu  $3,4 \pm 0,7$  cm, taş volümü  $22,3 \pm 10,2$  cm<sup>3</sup> idi. Ortalama operasyon süresi  $95,8 \pm 30,3$  dk olarak hesaplandı. Postoperatif 1. gün taşsızlık oranı %68, 3. Ayda %75 idi. 8 hastaya (%22,2) ikincil bir prosedür uygulandı (ekstrakorporeal şok dalga litotripsi (ESWL) veya fleksible üreterorenoskopi (F-URS)).

**Sonuç:** Uyguladığımız ‘Metilen mavisi tekniği’ retroperitonoskopik direkt görüş altında daha önce kısmen veya tamamen dilatasyon sağlananan kaliksi bularak böbreğe tekrar akses sağlanması için güvenli ve pratik bir seçenektir.

**Anahtar Kelimeler:** metilen mavisi, retroperitonoskopi, renal akses başarısızlığı, perkütan nefrolitotomi

### Abstract

**Objective:** To present our ‘methylene blue-guided retroperitoneoscopy technique’ that we apply in cases where extravasation develops for various reasons and is complicated as a result in Percutaneous Nephrolithotomy surgery (PNL).

**Material and Methods:** A total of 36 patients, who underwent PNL with the ‘methylene blue technique’ at Bakirkoy Dr. Sadi Konuk Training and Research Hospital between 2014 and 2020, were retrospectively evaluated. The study included only cases in which the ‘methylene blue-guided retroperitoneoscopy technique’ was used due to the inability to advance the Amplatz sheath to the targeted calyx due to renal scarring or a staghorn stone filling the targeted calyx, Amplatz sheath was withdrawn from the kidney with the guidewire due to the inattention of the assistant surgical team or contrast material extravasation. The patients’ demographic, preoperative, perioperative, and postoperative data were recorded, and stone-free and complication rates were noted.

**Results:** The mean age of the patients was 45.1 (36-55) years, the mean body mass index was  $27.8 \pm 4$  kg/m<sup>2</sup>, the mean stone size was  $3.4 \pm 0.7$  cm, and the mean stone volume was  $22.3 \pm 10.2$  cm<sup>3</sup>. The mean operation time was calculated as  $95.8 \pm 30.3$  minutes. The stone-free rate was 68% on the postoperative first day and 75% on the third month. Eight patients (22.2%) underwent a secondary procedure (extracorporeal shock wave lithotripsy or flexible ureterorenoscopy).

**Conclusion:** The ‘methylene blue-guided retroperitoneoscopy technique’ we apply under retroperitoneoscopic direct vision is a safe and practical option for re-accessing the kidney by locating the calyx, which is first partially or completely dilated.

**Keywords:** methylene blue, retroperitoneoscopy, renal access failure, percutaneous nephrolithotomy

The study was approved by University of Health Sciences, Bakırköy Dr.Sadi Konuk Training and Research Hospital Clinic Investigations Ethic Committee (Approval No: 2021-11-22, Date: 2021/11/15). All research was performed in accordance with relevant guidelines/regulations, and informed consent was obtained from all participants.

## INTRODUCTION

Percutaneous nephrolithotomy (PNL) is the primary and effective treatment method for kidney stones larger than 2 cm and lower calyceal stones over 1 cm that are unsuitable for extracorporeal shock wave lithotripsy (1). The three important stages of this operation are renal access, dilatation, and fragmentation. Failure to provide access to the targeted calyx, insufficient dilatation, Amplatz sheath being outside the kidney, and complications that may occur secondary to these significantly affect postoperative outcomes. Especially in patients with staghorn stones filling the targeted calyceal system and those with scarring secondary to previous kidney surgery, adequate dilatation may not be achieved even if calyceal access is provided (2).

Sometimes when the kidney is mobile, and the parenchyma is thin, and sometimes, due to the imprecision of the assistant surgical team, the Amplatz sheath may be withdrawn from the kidney together with the guidewire. In these cases, image quality deteriorates due to bleeding and contrast agent extraction, making it difficult to access the targeted calyx again. Although various alternative methods, such as ultrasonography (USG), endoscopy-assisted access, and an angio-catheter, have been proposed to achieve re-accession in such cases, there is still no consensus on the standard approach (2,3).

In this study, we aimed to present our experience with our previously undefined 'methylene blue-guided retroperitoneoscopy technique', which we applied in 36 PNL cases to provide access to the kidney where the Amplatz sheath could not be advanced to the targeted calyx due to the reasons as mentioned above, and all alternative access methods were also unsuccessful.

## MATERIAL AND METHODS

Patients who underwent PNL due to kidney stones at Bakirkoy Dr. Sadi Konuk Training and Research Hospital between 2014 and 2020 were retrospectively evaluated. We recorded the data of 36 cases in which we applied the 'methylene blue-guided retroperitoneoscopy technique', previously undefined in the literature, due to the inability to obtain perioperative access.

Among the patients aged 18 years and older, patients did not require intensive care follow-up. The study included only cases in which the 'methylene

blue-guided retroperitoneoscopy technique' was used due to the inability to advance the Amplatz sheath to the targeted calyx due to renal scarring or a staghorn stone filling the targeted calyx, Amplatz sheath was withdrawn from the kidney with the guidewire due to the inattention of the assistant surgical team or contrast material extravasation, in which re-access was achieved using the 'methylene blue-guided retroperitoneoscopy technique'.

Routine laboratory tests were performed on all the patients preoperatively. The sterility of the preoperative urine culture was ensured in the patients, and a contrast-enhanced examination [computer tomography (CT) or intravenous pyelography] was undertaken. The stone size was defined as the longest axis of the stone. Stone volume was estimated using the ellipsoid formula the European Association of Urology recommended ( $SV = \pi * l * w * d * 0.167$ ), where length, width, and depth constitute stone diameters measured in three axes (4). In the case of multiple stones, the dimensions of each stone were measured separately and then added.

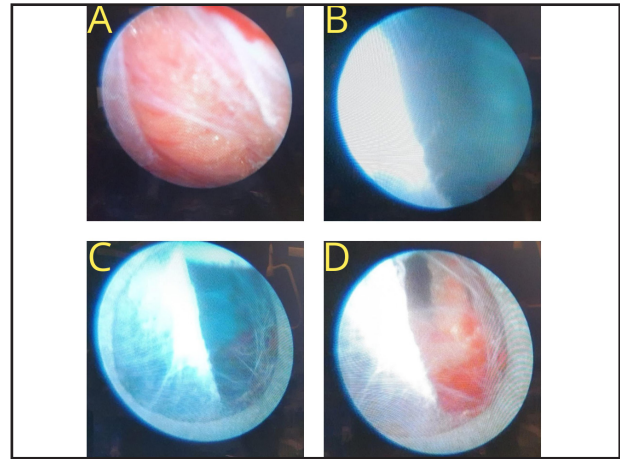
Parameters such as stone localization, presence of anomalies, and partial or complete staghorn stones were used to calculate Guy's stone score (GSS) (5). Operative time was defined as the time from entering the external urethral meatus to inserting the ureteral catheter to inserting the nephrostomy tube. Complications were evaluated according to the modified Clavien score (6). Fever was defined as a body temperature of  $>38^{\circ}\text{C}$ . Bleeding was defined based on the requirement of blood transfusion, bladder irrigation, or hospitalization.

Direct urinary system radiography was performed on the first postoperative day, and CT was performed on the third month. A residual stone fragment size of  $<4$  mm was considered stone-free.

## Surgical Technique

In all cases, a standard retrograde 5-French ureteral exchange catheter was placed in the renal pelvis in the lithotomy position. Then, fluoroscopic access was attempted by placing the patient in a prone position. Gradual dilatation was performed with a plastic dilator set. A 24-French nephroscope (Karl Storz GmbH & Co. KG, Tuttlingen, Germany) and a pneumatic lithotripter (Vibrolith®, Elmed, Ankara, Turkey) were used in all cases.

After imaging the calyceal system by injecting contrast material through the retrograde ureteral catheter and entering the targeted calyx with an 18-gauge needle, during the attempt to advance the coaxial guidewire to the renal pelvis, upper calyx, or ureter, the catheter can only be advanced to the targeted calyx in some cases due to the presence of a stone filling the calyx or insufficient hydronephrosis. Although gradual dilatation is performed with a plastic dilator set over the coaxial guidewire and the Amplatz sheath is placed, this sheath may remain at the parenchymal border or outside the kidney. Access may not be provided in cases where the stone has filled the targeted calyx, the coaxial guidewire cannot carry the dilator, the Amplatz sheath cannot be advanced to the calyx due to scarring secondary to previous kidney surgery, and in the presence of a mobile kidney and thin parenchyma. In addition, due to the imprecision of the assistant surgical team, the inserted Amplatz sheath may be withdrawn from the kidney together with the coaxial guidewire. There may also be some cases in which the Amplatz sheath is initially thought to be in the calyx, but when the nephroscope is entered, this sheath is visualized to have been left in the retroperitoneal space. Extravasation from the parenchymal defect is achieved by administering methylene blue diluted with 0.9% saline at 1/10 through the ureteral catheter with a slow and continuous flow. Under direct view of the nephroscope located in the retroperitoneum, a renal parenchymal defect is sought around the blue area. After the opening in the renal parenchyma is located, if it is wide enough for the nephroscope to enter, the nephroscope is directly entered into the calyx. Then, the Amplatz sheath is advanced to the calyceal system over the nephroscope. Suppose the opening in the parenchyma is not wide enough for the nephroscope to pass through. In that case, the coaxial guidewire is sent into the system through this opening, and access is provided by re-dilating it (Figure). During retroperitoneoscopy, vascular structures in the perirenal region can be seen with direct examination. In addition, during Retroperitoneoscopy, the advanced level of the nephroscope should be intermittently checked with fluoroscopy to avoid possible trauma to the renal pedicular structures. A drainage catheter can be used in cases where the retroperitoneoscopy proce-



**Figure:** A. Retroperitoneoscopic view. B. Orientation towards the region where methylene blue comes from. C. Locating the calyx orifice. D. The appearance of the calyx after the end of the methylene blue infusion.

dures takes a long time, and there is reluctance due to the extravasation of fluid in the retroperitoneal area.

## RESULTS

The mean age of the patients was  $45.1 \pm 4.8$  years, and their mean body mass index was  $27.8 \pm 4$  kg/m<sup>2</sup>. Ten patients (27.7%) had a previous history of stone surgery on the same side. The mean stone size was calculated as  $3.4 \pm 0.7$  cm, and the mean stone volume was  $22.3 \pm 10.2$  cm<sup>3</sup>. Nineteen (52.8%) procedures were performed on the right side and 17 (47.2%) on the left side. Table 1 presents the patients' demographic data, including the degree of stone-related hydronephrosis and the distribution of GSS values.

The mean operative time was calculated as  $95.8 \pm 30.3$  minutes. A perioperative double-J stent was placed in 16 (44.4%) patients. The stone-free rate was 68% on the postoperative first day and 75% on the third month. Kidney access could not be achieved in one case, and the operation was left to the second session. Eight patients (22.2%) underwent a secondary procedure (Table 2). In the early postoperative period, fever was observed in two (5.5%) patients, transient creatinine elevation in two (5.5%), blood transfusion in one (2.7%), and urinary system infection in one (2.7%). A double-J stent was inserted in one (2.7%) patient due to a urinary system leak. No Clavien Grade 3b, 4, or 5 complications were observed in our patients. Data on complications are shown in Table 3.

**Table 1.** Demographic data of the patients

Parameters	Mean ± SD
Age (years)	45.1 ± 4.8
BMI (kg/m <sup>2</sup> )	27.8 ± 4
ASA (n; %)	
1	5 (13.8)
2	25 (69.4)
3	6 (16.6)
Previous Surgery (n; %)	10 (27.7)
Side (n; %)	
Right	19 (52.7)
Left	17 (47.2)
Hydronephrosis (n % %)	
0	8 (22.2)
1	11 (30.5)
2	10 (27.7)
3	5 (13.8)
4	2 (5.5)
Guy's Stone Score (n ; %)	
1	7 (19.4)
2	10 (27.7)
3	12 (33.3)
4	7 (19.4)
Stone Diameter (cm)	3.4 ± 0.7
Stone Volume (cm <sup>3</sup> )	22.3 ± 10.2

SD: standard deviation, BMI: body mass index, ASA: American Society of Anesthesiologists

**Table 2.** Perioperative and postoperative data

Parameters	Mean ± SD
Reason to Perform (n ; %)	
Renal scarring	10 (27.7)
Staghorn stone filling the targeted calyx	20 (55,5)
Imprecision of the assistant surgical team	2 (5.5)
Massive contrast material extravasation	4 (11.1)
Operative Time (min)	95.8 ± 30.3
Double-J Stent Placement (n; %)	16 (44.4)
Additional Procedure (n; %)	
SWL	6 (16.6)
RIRS	2 (5.5)
SFR (n; %)	
First day	68
Third month	75
Length of Stay (day)	3 ± 1.6

SD: standard deviation, SWL: shock wave lithotripsy, RIRS: retrograde intrarenal surgery, SFR: stone-free rate

**Table 3.** Complications according to the Clavien-Dindo classification

	n (%)
<b>Grade 1</b>	
Fever	2 (5.5)
Temporary elevation in creatinine	2 (5.5)
<b>Grade 2</b>	
Blood transfusion requirement	1 (2.7)
Urinary system infection	1 (2.7)
<b>Grade 3a</b>	
Double-J stent requirement >24 h	1 (2.7)

## DISCUSSION

It has been reported that appropriate patient selection, sufficient surgical experience, and adequate equipment are required to perform PNL surgery (7) successfully. Renal access, dilatation, and fragmentation are the three important stages of this operation. The safety and success of surgery are affected by the structure of the calyx planned to be accessed (8).

Despite the increase in surgical experience and technological developments, many complications are still encountered in PNL operations, and most of these complications are seen during the preoperative dilatation stage. The immediate identification of complications and early intervention plays an important role in this process (9).

In the literature, the inability to achieve access during PNL has been reported at 2% among urologists and 9% among radiology doctors (10).

The reasons for this access failure have been listed as insufficient dilatation, the stone filling the targeted calyx, the guidewire not carrying the dilator, the Amplatz sheath not advancing to the calyx due to scarring secondary to previous kidney surgery, presence of a mobile kidney and thin parenchyma, the Amplatz sheath being withdrawn from the kidney together with the guidewire due to the imprecision of the assistant surgical team, and the Amplatz sheath being mistakenly considered to be inside the kidney when it is actually outside the kidney as confirmed under a nephroscope (11).

Extravasation due to the lack of access is undesirable, but extravasation that obscures the fluoroscopy

area is extremely rare. When severe extravasation occurs, fluoroscopy-guided puncture becomes very difficult and impossible. Even if the puncture is performed, the dilatation phase becomes open to complications due to the incomplete understanding of the calyceal anatomy due to extravasation. Various alternative methods have been proposed to provide access in such cases, e.g., furosemide injection, use of more concentrated contrast material, air pyelogram, and USG-assisted access (11). Khan et al. (12) and Grasso et al. recommended endoscopy-assisted access (13), while Giannakopoulos et al. suggested that an angiographic catheter could be used for this purpose (3).

Khan et al. (12) provided percutaneous access to 12 patients with flexible urethroscopy and emphasized that the ureteroscope facilitated access since it stabilized the kidney. Two of the 12 patients required a second surgical procedure, and the operation was terminated in one of these patients due to intraoperative bleeding. In another patient, additional surgery with urethroscopy was required due to a 12-mm stone in the anterior calyx, which could not be reached using the nephroscope.

Grasso et al. (13) also presented their series of seven cases in which they provided percutaneous access under flexible urethroscopy. One of their seven patients had a severe perirenal hematoma after a previous attempt to perform a nephrostomy. The authors stated that they applied this method because three patients had anterior calyceal stones, and dilatation was not possible in a further three cases due to staghorn stones. In all cases, they reported that percutaneous access was



performed in <30 minutes.

Giannakopoulos et al. (3), sharing their seven-year PNL experience, reported that fluoroscopic percutaneous access could be achieved using an angiographic catheter after an unsuccessful puncture in four patients. They stated that extravasation occurred due to high pressure after manual contrast injection into the pelvicalyceal system in two of these four patients and following more than one unsuccessful calyx puncture in the remaining two patients. They achieved successful access in all patients with the method they described.

Our study showed that re-entry into the targeted calyx was possible with the 'methylene blue-guided retroperitoneoscopy technique', which we defined and used after an unsuccessful access attempt. Due to extravasation, the stone-free rate decreases following difficulties in reaching the stone when entering a distinct calyx other than the targeted calyx. Our method provided access to the targeted calyx and positively affected the operation's success. With this method, which we explained in detail in the surgical technique section, we achieved easy re-entry into the targeted calyx in 35 of the 36 patients. Thus we obtained a stone-free rate similar to the literature. A study by He et al. defined a method to be protected from x-ray effects by integrating a punched frame into the ultrasound probe. In this method, access was verified by giving methylene blue from the ureteral catheter after access was provided. A puncture frame is effective and safe and reduces the complication rates while providing ultrasound-guided renal access in percutaneous nephrolithotomy (14).

Generally, an unsuccessful operation is distressing for both the patient and the surgeon (15). Furthermore, having to receive anesthesia for the second time for the operation and related psychological effects result in a very difficult process for the patient. If possible, completing the operation in a single session is more appropriate to avoid these unfavorable situations (16,17).

The perioperative and postoperative early complication rates and surgical results of the patients whose operations were completed with the described method were consistent with the standard PNL results reported in the literature. By applying this method, we con-

sider that we prevented kidney parenchymal damage that might occur with separate access. In addition, by ensuring access in a single session, we believe that we avoided the negative effects of the anesthesia being applied again and further psychological trauma for the patient due to a second procedure.

The strengths of our study are that it is the first of its nature in the literature, and we presented a new technique that can contribute to the literature. The limitations of our study include its retrospective design and the small number of patients included in the sample. Another limitation is the results reported from a single center and the absence of comparison between complicated and uncomplicated PNL cases. Further studies are needed in this regard.

## CONCLUSION

In PNL operations, the 'methylene blue-guided retroperitoneoscopy technique' is a fast, safe, and practical option that provides direct retroperitoneoscopic vision to locate and re-access the calyx, which we apply in cases where access cannot be achieved due to extravasation.

## Conflict of Interest

The authors declare to have no conflicts of interest.

## Financial Disclosure

The authors declared that this study has received no financial support.

## Informed Consent

Informed consent was obtained from all individual participants included in the study.

## Ethical Approval

The study was approved by University of Health Sciences Bakırköy Dr.Sadi Konuk Training and Research Hospital Clinic Investigations Ethic Committee (Approval No: 2021-11-22, Date: 2021/11/15) and written informed consent was received from all participants. The study protocol conformed to the ethical guidelines of the Helsinki Declaration.

### Author Contributions

Conception and design; SK, ME, Data acquisition; SK, ME, Data analysis and interpretation; SK, ME, Drafting the manuscript; SK, ME, Critical revision of the manuscript for scientific and factual content; SK, Statistical analysis; ME, Supervision; SK, ME.

### REFERENCES

1. Fernstrom I, Johansson B. Percutaneous pyelolithotomy. *Scand J Urol Nephrol*. 1976; 10(3):257–9. DOI: 10.1080/21681805.1976.11882084.
2. Peng P-X, Lai S-C, Seery S, He Y-H, Zhao H, Wang X-M, et al. Balloon versus Amplatz for tract dilation in fluoroscopically guided percutaneous nephrolithotomy: a systematic review and meta-analysis. *BMJ Open*. 2020; 10(7):035943. DOI: 10.1136/bmjopen-2019-035943.
3. Giannakopoulos S, Bantis A, Kalaitzis C, Touloupidis S. Use of an angiographic catheter to facilitate fluoroscopy-guided percutaneous renal access in cases with diffuse contrast extravasation. *J Endourol*. 2010; 24(10):1575–8. DOI: 10.1089/end.2010.0019.
4. Tiselius H-G, Andersson A. Stone burden in an average Swedish population of stone formers requiring active stone removal: how can the stone size be estimated in the clinical routine? *Eur Urol*. 2003; 43(3):275–81. DOI: 10.1016/s0302-2838(03)00006-x.
5. Thomas K, Smith NC, Hegarty N, Glass JM. The Guy's stone score--grading the complexity of percutaneous nephrolithotomy procedures. *Urology*. 2011; 78(2):277–81. DOI: 10.1016/j.urology.2010.12.026.
6. Tefekli A, Ali Karadağ M, Tepeler K, Sari E, Berberoglu Y, Baykal M, et al. Classification of percutaneous nephrolithotomy complications using the modified clavien grading system: looking for a standard. *Eur Urol*. 2008; 53(1):184–90. DOI: 10.1016/j.eururo.2007.06.049.
7. Kim SC, Kuo RL, Lingeman JE. Percutaneous nephrolithotomy: an update. *Curr Opin Urol*. 2003; 13(3):235–41. DOI: 10.1097/00042307-200305000-00012.
8. Desai M. Ultrasonography-guided punctures-with and without puncture guide. *J Endourol*. 2009; 23(10):1641–3. DOI: 10.1089/end.2009.1530.
9. Kyriazis I, Panagopoulos V, Kallidonis P, Özsoy M, Vasilas M, Liatsikos E. Complications in percutaneous nephrolithotomy. *World J Urol*. 2015; 33(8):1069–77. DOI: 10.1007/s00345-014-1400-8.
10. Türk C, Neisius A, Petřík A, Seitz C, Thomas K, Skolarikos A. EAU Guidelines on Urolithiasis 2020. Available at [https://d56bochluxqnz.cloudfront.net/documents/full-guideline/EAU-Guidelines-on-Urolithiasis-2022\\_2022-03-24-142444\\_crip.pdf](https://d56bochluxqnz.cloudfront.net/documents/full-guideline/EAU-Guidelines-on-Urolithiasis-2022_2022-03-24-142444_crip.pdf).
11. Miller NL, Matlaga BR, Lingeman JE. Techniques for Fluoroscopic Percutaneous Renal Access. *Journal of Urology*. 2007; 178:15–23. DOI: 10.1016/j.juro.2007.03.014.
12. Khan F, Borin JF, Pearle MS, McDougall EM, Clayman R V. Endoscopically guided percutaneous renal access: “seeing is believing”. *J Endourol*. 2006; 20(7):451–5; discussion 455. DOI: 10.1089/end.2006.20.451.
13. Grasso M, Lang G, Taylor FC. Flexible ureteroscopically assisted percutaneous renal access. *Tech Urol*. 1995; 1(1):39–43. PMID: 9118366.
14. He X-B, Liu Y-Y, Huang G-M, Du D. The Clinical Application of Puncture Frame in Establishing Ultrasound Guided Percutaneous Nephrolithotomy Access. *Urol J*. 2020; 17(4):358–62. DOI: 10.22037/uj.v0i0.5587.
15. Arafa MA, Rabah DM. Study of quality of life and its determinants in patients after urinary stone fragmentation. *Health Qual Life Outcomes*. 2010; 8:119. DOI: 10.1186/1477-7525-8-119.
16. Gadzhiev N, Brovkin S, Grigoryev V, Dmitriev V, Baketin P, Obidnyak V, et al. Are we ready to predict percutaneous nephrolithotomy (PCNL) stone-free failure? *J Clin Urol [Internet]*. 2016; 9(1):11–8. DOI: 10.1177/2051415815584505.
17. Dawaba MS, Shokeir AA, Hafez AT, Shoma AM, El-Sherbiny MT, Mokhtar A, et al. Percutaneous nephrolithotomy in children: early and late anatomical and functional results. *J Urol*. 2004; 172(3):1078–81. DOI: 10.1097/01.ju.0000134889.99329.f7.