

Primitive neuroectodermal tumor / Ewing sarcoma (pnet/ews) of the kidney: Report of a case

Böbreğin primitif nöroektodermal tümörü / Ewing sarkomu (pnet/ews): Olgu sunumu

Muhammet Fuat Özcan¹, Hayriye Tatlı Dogan², Ziya Akbulut¹, Ayse Nur Özcan³, Olcay Kandemir⁴, Kemal Ener¹,
Mevlana Derya Balbay⁵

¹ Ankara Atatürk Eğitim ve Araştırma Hastanesi, Üroloji Kliniği, Ankara

² Ankara Atatürk Eğitim ve Araştırma Hastanesi, Patoloji Kliniği, Ankara

³ Ankara Atatürk Eğitim ve Araştırma Hastanesi, Radyoloji Kliniği, Ankara

⁴ Onkoloji Eğitim ve Araştırma Hastanesi, Patoloji Kliniği, Ankara

⁵ Memorial Şişli Hastanesi, Üroloji Kliniği, Ankara

Geliş tarihi (Submitted): 15.07.2016

Kabul tarihi (Accepted): 02.09.2016

Yazışma / Correspondence

Muhammet Fuat Özcan

Ankara Atatürk Eğitim ve Araştırma

Hastanesi, Üroloji Kliniği, Ankara

Tel: 0505 640 7025

E-mail: mfuatozcan@hotmail.com

Özet

Sol yan ağrısı ile başvuran 44 yaşındaki bir vaka sunuldu. Bilgisayarlı karın tomografisinde sol böbrek üst polünde yer alan renal kitle saptandı. Hastaya sol radikal nefrektomi ve adrenalectomi yapıldı. Cerrahi örneğin patolojik inceleme sonucunda böbreğin primitif nöroektodermal tümör / Ewing sarkomu saptandı. Nispeten nadir olan bu tümörün klinik bulguları, görüntüleme bulguları ve tanısı tartışıldı.

Anahtar Kelimeler: Ewing sarkomu, primitif nöroektodermal tümör, renal kitle

Abstract

The case of a 44-year-old man who presented with left flank pain is reported. Computer tomography of the abdomen revealed a left renal mass replacing upper pole of the kidney. The patient underwent left radical nephrectomy and adrenalectomy. Pathologic examination of the surgical specimen revealed the primitive neuroectodermal tumour / Ewing sarcoma of the kidney. The clinical presentation, imaging findings and diagnosis of this relatively rare tumor are discussed.

Keywords: Ewing sarcoma, primitive neuroectodermal tumor, renal mass

Introduction

PNET/EWS consist of malignant round small cell tumors and originate from neuroectoderma. PNET/EWS is a very aggressive neoplasm that predominantly affects children and adolescents, very rare in patients more than

40 years of age and occur most commonly in bone, soft tissues (1,2). PNET/EWS in genitourinary system is very rare and primary renal PNET/EWS is extraordinarily rare (3). Radiological features were not sufficient to differentiate this lesion from renal cancer. Immunohistochemistry

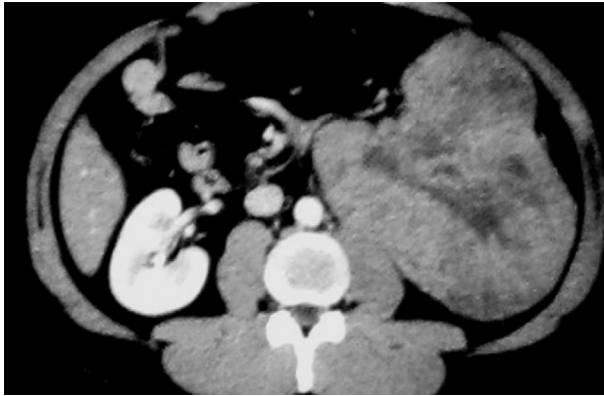

Figure 1. CT scan with contrast enhancement showing left renal mass

and/or molecular pathologic examination can allow a better differential diagnosis of renal tumors. We present a case of primitive PNET/EWS of the kidney in a 44-year-old man having left flank pain.

Case Report

A 44-year-old man presented with left flank pain. Computer tomography (CT) of the abdomen revealed a 166x153-mm left renal mass replacing upper pole of the kidney including areas of low attenuation consistent with necrosis showed mild enhancement after intravenous contrast (Figure 1). There was no evidence of distant metastatic disease.

The patient underwent a left radical nephrectomy and left adrenalectomy with paraaortic lymph node dissection. Pathologic examination revealed primitive neuro-

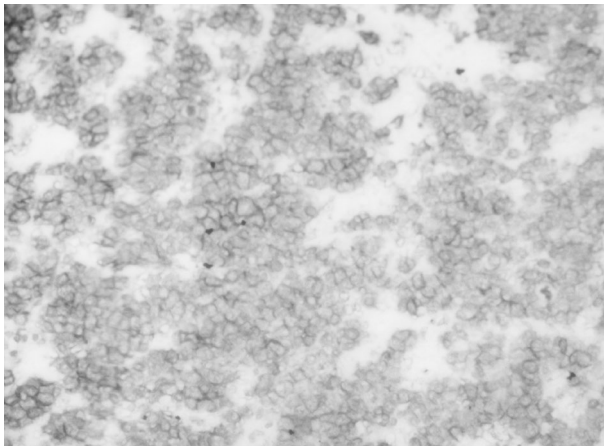


Figure 2. Microscopic examination of the section of the kidney shows diffuse proliferation of blue round small cell tumor. The tumor cells have scanty cytoplasm and salt-and-pepper chromatin. In some areas, the tumor shows the characteristic Homer-Wright rosettes (hematoxylin-eosin, magnification x40).

ectodermal tumor / Ewing sarcoma (PNET/EWS) of the kidney. The renal pelvis adipose tissue around the renal pelvis was involved with the tumor, whereas renal pelvis, surgical margins, the ureter, the adrenal gland and lymph nodes were negative for tumor involvement.

Histopathologically the tumor was composed of small uniform, round cells with finely dispersed chromatin and micronucleolus. Numerous mitotic figures were seen. In some areas, the tumor showed the characteristic Homer-Wright rosettes (Figure 2). Immunohistochemically tumor cells showed membranous staining with CD99 (Figure 3) and cytoplasmic staining with vimentin. Neuron specific enolase was expressed focally. The tumor cells were negative for synaptophysin, chromogranin, S100, LCA, cytokeratin markers (AE1/3 and Cam 5.2) and WT1. Therefore, histopathologic evaluation suggested PNET (Figures 2 and 3).

Morphology and the immunohistochemical panel helped for exclusion of neuroblastoma, non-Hodgkin lymphoma and Wilms tumor. Chromosomal translocation was detected at EWSR1 (Ewing sarcoma breakpoint region) gene locus in tumor cells by fluorescence in situ hybridization (FISH). This translocation was consistent with PNET/EWS (Figure 4).

Patient was consulted with medical and radiation oncologist and chemotherapy with alternating courses of vincristine, cyclophosphamide, doxorubicin, ifosfamide and etoposide was commenced.

Discussion

There is no specific clinical, radiological and laboratory finding for primary renal PNET/EWS. Patients often have non-specific symptoms. The classic triad is, hematuria, pain and palpable masses can occurs in patients with renal PNET/EWS (4). The laboratory findings are usually within the normal range. The CT and MRI findings of PNET/EWS are non-specific, but they are useful for the detection of local/distant metastases. Radiological features were not sufficient to differentiate this lesion from renal cancer. Therefore, the diagnosis of PNET/EWS is very difficult without pathologic evaluation.

Neuroectodermal origin had been proposed based upon variable expression of neuronal, immunohistochemical (IHC) markers, cytogenetic, and ultrastructural features (5). Diagnosis needs confirmation with immu-

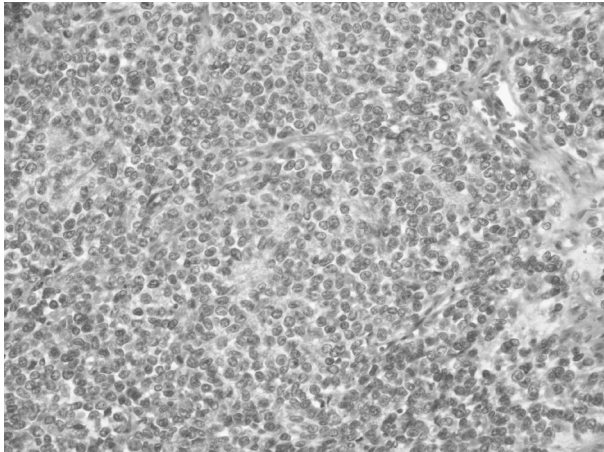


Figure 3. Immunohistochemistry for CD 99 antibody showed that tumor cells have strong membranous positivity (magnification x40).

nohistochemistry and/or molecular pathologic examination. FISH analysis can distinguish small round cell tumors with similar morphologic and IHC features. Advances in IHC allow a better differential diagnosis of renal tumors. Likely the incidence of PNET/EWS increases with time.

The treatment for renal PNET/EWS consists of surgery, chemotherapy, and radiotherapy. PNET/EWS has a poor prognosis for patients with M1 disease; chemotherapy is an effective strategy in M1 disease and probably also in M0 disease (6). Current standard chemotherapy includes doxorubicin, vincristine and cyclophosphamide alternated with ifosfamide and etoposide (7).

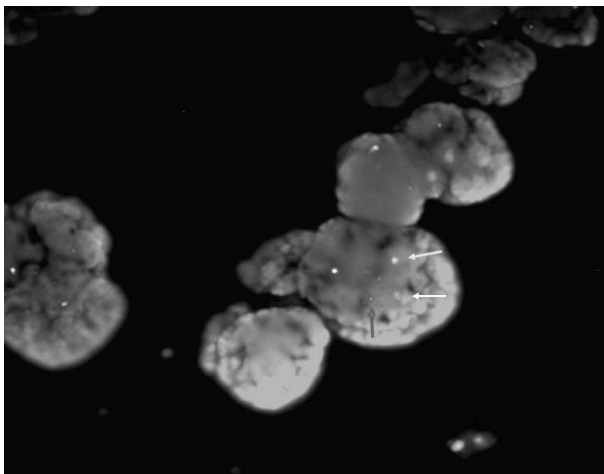


Figure 4. Result of EWSR1: (22q12) dual color break apart rearrangement probe by FISH method. Many cells show normal copy of EWS as shown by fusion signal pattern (yellow arrow), and rearranged EWS locus as shown by the presence of widely spaced orange (red arrow) and green (green arrow) signals.

We herein presented a 44 years old adult patient with renal PNET, which is extremely rare in this location and in adult population. Follow up was carried out at 3 months and 6 months after surgery. Results were normal and the patient followed by medical oncologists.

PNET, which has a different management and chemotherapy regimen compared to renal cell carcinoma, should be considered in the differential diagnosis of renal tumors in adult population.

References

1. Toskos M. Peripheral primitive neuroectodermal tumors: Diagnosis, classification and prognosis. *Perspect Pediatr Pathol* 1992;16:27-98.
2. Horowitz ME, Delaney TF, Malawer MM, Woo SY, Hicks MJ. Ewing's sarcoma of bone and soft tissue and peripheral primitive neuroectodermal tumor. In: Pizzo PA, Poplack PG, editors. *Principles and practice of pediatric oncology*. Philadelphia7 Lippincott; 1997. p.831- 63.
3. Parham DM, Roloson GJ, Feely M, Green DM, Bridge JA, Beckwith JB. Primary malignant neuroepithelial tumors of the kidney: a clinicopathologic analysis of 146 adult and pediatric cases from the National Wilms' Tumor Study Group Pathology Center. *Am J Surg Pathol* 2001;25:133-46.
4. Ellinger J, Bastian PJ, Hauser S, Biermann K, Müller SC. Primitive neuroectodermal tumor: rare, highly aggressive differential diagnosis in urologic malignancies. *Urology* 2006;68:257-62.
5. McKeon C, Thiele CJ, Ross RA, Kwan M, Triche TJ, Miser JS, Israel MA. Indistinguishable patterns of protooncogene expression in two distinct but closely related tumors: Ewing's sarcoma and neuroepithelioma. *Cancer Res* 1988;48:4307-11.
6. Risi E, Iacovelli R, Altavilla A, Alesini D, Palazzo A, Mosillo C, et al. Clinical and pathological features of primary neuroectodermal tumor/Ewing sarcoma of the kidney. *Urology* 2013;82:382-386.
7. Grier HE, Krailo MD, Tarbell NJ, Link MP, Fryer CJ, Pritchard DJ, et al. Addition of ifosfamide and etoposide to standard chemotherapy for Ewing's sarcoma and primitive neuroectodermal tumor of bone. *N Engl J Med* 2003;348:694-701.