

Spontan Renal Arter Anevrizma Rüptürü ve Endovasküler Tedavisi

Spontaneous Renal Artery Aneurysm Rupture And Its Endovascular Treatment

Arif Aydın¹, Muzaffer Tansel Kilinc¹, Gokhan Ecer¹, Osman Koc², Mehmet Giray Sonmez¹, Mehmet Balasar¹

¹ NEÜ Meram Medicine Faculty Department of Urology, Konya, Turkey

² NEÜ Meram Medicine Faculty Department of Radiology, Konya, Turkey



Geliş tarihi (Submitted): 17.07.2018

Kabul tarihi (Accepted): 22.08.2019

Yazışma / Correspondence

Arif Aydın, M.D.

ORCID: 0000-0001-8691-090X

Department of Urology NEÜ Meram
Medicine Faculty, Konya, Turkey

Tel: +90 332 223 7441

Mobil: +90 505 556 6988

E-mail: aydinarif@gmail.com



Bu eser [Creative Commons Atf-
GayriTicari 4.0](https://creativecommons.org/licenses/by-nc/4.0/) Uluslararası Lisansı
ile lisanslanmıştır.

Özet

Renal arter anevrizması, renal arterin, dallarının veya her ikisinin de elastik dokularının ve arteriyel duvar yapısının zayıflaması nedeniyle lokal olarak genişlemesine denir. Poutasse sınıflamasına göre sakküler, fuziform, disseke ve intrarenal olmak üzere dört temel tipi vardır.

Özellikle son yıllarda artan endovasküler tedavi tecrübesi ve teknoloji ile bağlantılı olarak, renal arter anevrizması tedavisinde endovasküler tedavinin öncelikli olduğunu belirten çalışmalarda da bir artış söz konusudur.

Bu olgu sunumundaki amacımız endovasküler olarak tedavi edilen 3 cm'lik sol renal arter sakküler anevrizma rüptürlü hastayı sunmak ve literatür eşliğinde tartışmaktır.

Anahtar Kelimeler: renal arter anevrizması, endovasküler tedavi, spontan rüptür

Abstract

Renal artery aneurysm is the local expansion of renal artery, its branches or both due to the weakening of the elastic tissue and media of arterial wall structure. It has four basic types as saccular, fusiform, dissected and intrarenal based on Poutasse classification, there is a gradual increase in proofs and study results showing that endovascular treatment should be preferred in renal artery aneurysm treatment in correlation with the endovascular experience and technology improving especially in recent years.

Our aim in this case presentation was to present the left renal artery saccular aneurysm rupture patient treated endovascularly and discuss with literature.

Keywords: renal artery aneurysm, endovascular treatment, spontaneous rupture

INTRODUCTION

Renal artery aneurysm rupture is one of the rare causes for suddenly starting side pain and stomach ache and its prevalence in the general population changes between 0.09 and 0.3%. It has four basic types as saccular, fusiform, dissected and intrarenal based on Poutasse classification. (1) Saccular, fusiform and dissected aneurysms constitute 70%, 22.5% and 12% of the cases in order. (2) There are no patognomonic symptoms and findings accompanying renal artery aneurysm. In addition to admittance complaints such as hypertension (55-75%), hematuria (30%) and side pain (1%) and hypertension-related headache (%11), the patient can also be asymptomatic. (3) Abdominal murmur can be helpful for diagnosis and is detected nearly in 10% of the patients. Hematuria can be microscopic or macroscopic. In its etiology, it is claimed that hypertension, thrombosis of small vessels and microinfarcts can be responsible. The certain diagnosis is the demonstration of the lesion with angiography. Peripheral dissection, thrombosis, renal infarctus, bleeding and rupture are the potential complications of renal artery aneurysms. (4) Factors creating rupture tendency are incomplete calcification or lack of calcification, aneurysm diameter over 2 cm and accompanying hypertension and/or pregnancy. (1)

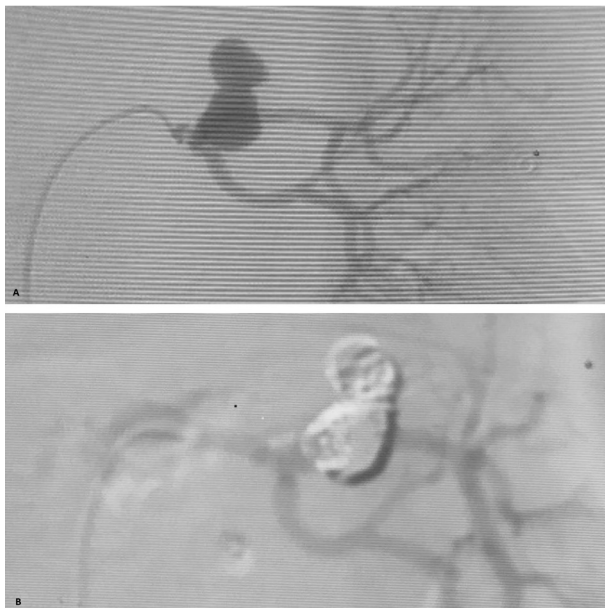


Figure 1 A: Renal Artery Aneurysm B: Renal Artery Aneurysm After Occlusion

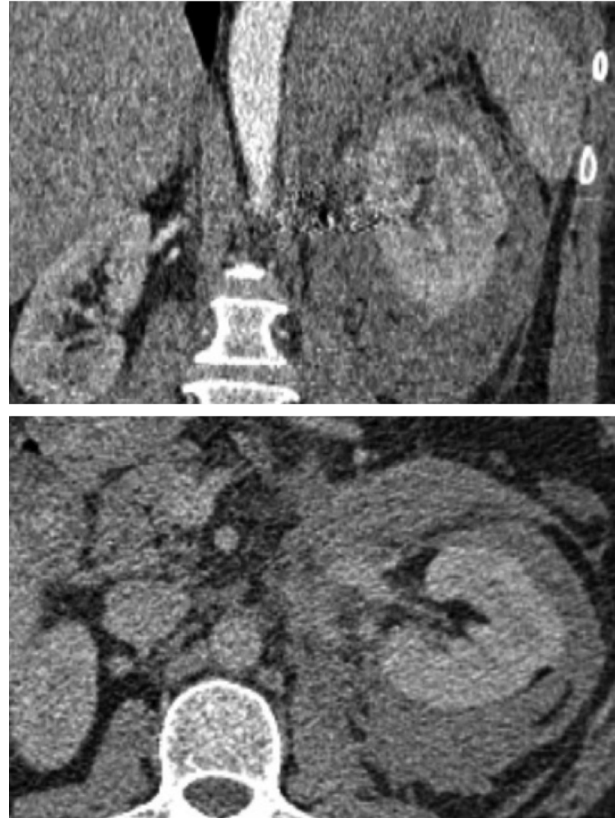


Figure 2 Perirenal Hematoma

A completely calcified renal artery aneurysm of 2 cm and below can be followed-up in a patient with normal asymptomatic tension. Surgical removal indications without considering size in renal artery aneurysm are aneurysms causing renal ischemia and hypertension, dissect aneurysms, aneurysms with local symptom such as side pain and hematuria, pregnant women or women planning pregnancy, aneurysms observed to enlarge in serial radiography and thrombus containing aneurysms distal embolism symptom. Asymptomatic and completely uncalcified aneurysms under 2 cm without any of these criteria can be treated without surgery. A certain indication definition is not available for surgical intervention in asymptomatic patients with aneurysms over 2 cm diameter and none of the criteria above. (1)

CASE PRESENTATION

A 44-year old female patient admitted to the emergency service with a sudden left side pain, restlessness and weakness complaints present for six hours.

The patient had no story of hematuria, trauma, stone disease or urological surgery. She also didn't have any additional diseases other than regulated hypertension. Vital findings were normal and stable. Abdomen was relaxed and there was left costovertebral angle sensitivity but no abdominal murmur. Other system examinations were normal. Biochemical values and urine test were in normal borders and hemoglobin value was 10.1 g/dl based on laboratory examination. An actively bleeding saccular aneurysm with a diameter of 30 mm in left main renal artery and an approximately 5x7 cm hematoma area in left perirenal area were observed in complete abdomen tomography with contrast. Renal artery angioembolization was planned for the patient whose Glasgow coma scale regressed to 13, pulse increased to 100/min and hemoglobin value regressed to 8.4 g/dl in the fourth hour of the follow-up.

Technique

Selective catheterization (5F Cobra) of the renal artery was performed. A nearly 30 mm saccular type aneurysm caused by interlobar artery which is a branch of left renal artery was observed in the angiography. The microcatheter (Headway; Terumo Medical, CA, USA) was placed through the renal artery in an attempt to approach the lesion. Aneurysm was occluded to detachable microcoils (Microvention Microcoil, CA, USA). Control angiography reveals total occlusion of the aneurysm.

Aneurysm was completely occluded in postoperative angiography and no complications occurred during the operation. During 16 days of hospitalization, the patient was given six units of erythrocyte suspensions due to anemia. The patient was discharged without any problems on the 16th day of the follow-up. The patient was normal and didn't have any significant symptoms in 3rd, 6th, 12th, 18th month controls.

DISCUSSION

Very few cases with successful endovascular treatment for renal artery aneurysm and rupture have been reported in recent years. Two methods have been reported for endovascular treatment. First is the coiled embolization of aneurysm to block renal blood flow

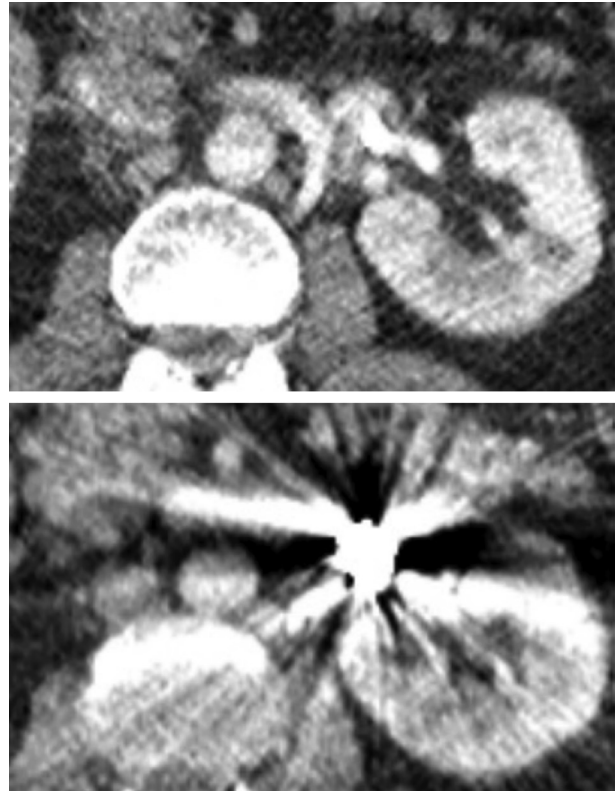


Figure 3 Post Embolization 6th Month Control Images

without damaging, (5) and the second is provision of flow continuity by locating arterial stent on the branches causing aneurysm and effectively deactivating aneurysm. (6)

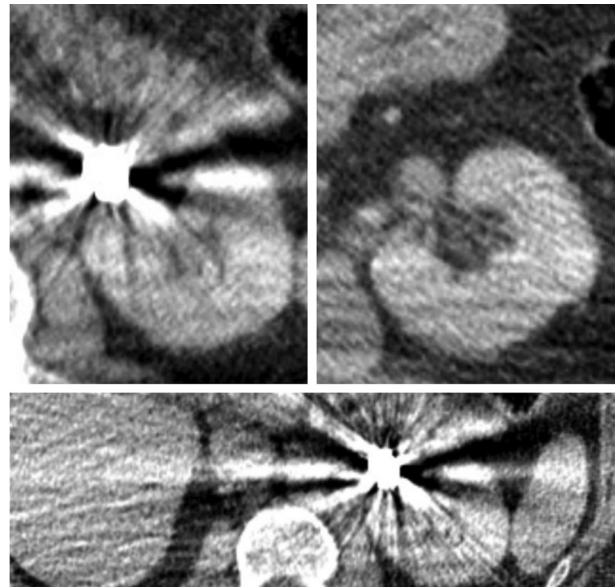


Figure 4 Post Embolization 18th Month Control Images

In the case presentation by Wei Hb et al, two aneurysms in renal artery primary bifurcations with diameters of 1.8 and 1.2 cm in a patient were successfully resected using Robot guided laparoscopic approach. (7) In the retrospective study by Guo H et al, 27 patients treated with transarterial embolisation due to iatrogenic renal pseudoaneurysm and arteriovenous fistula were covered and technical and clinical success ratios were detected as 100% and 96.3% in order (8).

In the study by Wei X et al, 28 renal artery aneurysm patients were treated with stent guided embolization method and technical success ratio was detected as 100%. (9) In the case presentation by Nassiri N, the patient with 2.5 cm extraparenchymal and saccular left renal artery aneurysm was endovascularly treated with stent guided microcil embolization method without any complications. (10) In the case presentation by J. Sousa, the patient with a 21 mm renal artery aneurysm was endovascularly treated successfully. (11) In the study by Bracale Um et al, three patients with renal artery aneurysm were successfully treated and no early or late term complications were detected. (12)

In the case presentation by Adrahtas D et al, a solitary kidney patient with 2.8 cm left renal artery aneurysm was treated with endovascular method. (13) In the case presentation by Koter S H, the patient with 6 cm right renal artery aneurysm had a successful endovascular treatment. (14) In the study presented by Chung R et al, a patient with 9 renal artery aneurysms with an average aneurysm diameter of 21 mm was endovascularly treated with 100% technical success. (15) In the study by Li G et al, the patient with six ruptured renal artery aneurysms was treated endovascularly and complete occlusion was detected in four patients in the observation lasting 25 months in average.(16) In the study by Tsilimparis N et al, out of 40 patients with 44 renal artery aneurysms, 24 were treated with endovascular and 20 were treated with open surgery and endoscopic treatment was presented to be as safe and efficient as open surgery. (17) In the study by Sedat J et al including 15 patients, 18 renal artery aneurysms were treated endovascularly with 100% technical success ratio.(18) As seen in literature, there is a gradual

increase in proofs and study results showing that endovascular treatment should be preferred in renal artery aneurysm treatment in correlation with the endovascular experience and technology improving especially in recent years.

In our case, a nearly 3 cm and spontaneously bleeding aneurysm was treated with angioembolization and no functional problems were observed in long-term follow-ups and renal blood flow wasn't deteriorated and aneurysm was occluded and had a stable course. In line with literature, endovascular treatment ended quite successfully in our case, too.

We think that renal artery aneurysm endovascular treatment should be applied in selected centers and on suitable patients as a minimal invasive method.

CONCLUSION

Renal artery aneurysm rupture is one of the rare causes for suddenly starting side pain and stomach ache and requiring urgent urological surgical intervention. Although surgical intervention is the primary treatment option today, proof for successful and efficient aneurysm rupture treatment with endovascular treatment also increases gradually. We think that successful results of this treatment method will be shared more in the future cases and studies.

Acknowledgements

Conflict of interest: None of the authors have any potential conflict of interest.

Funding: The authors received no financial support for the research, authorship, and/or publication of this article.

REFERENCES

1. Campbell-Walsh Urology 10th Edition
2. Bulbul MA, Farrow GA. "Renal artery aneurysms." Urology 1992; 40: 124-6.
3. Deterling RA. "Aneurysm of the visceral arteries". J Cardio-vasc Surg 1981; 12: 309-322.
4. Poutesse EF. Renal artery aneurysms: their natural history and surgery. J Urol 1966; 95: 297.
5. Halloul Z, Buerger T, Grote R, et al."Selective embolization of a renal artery aneurysm". Vasa. 2000 Nov; 29:285-7.
6. Pershad A, Heuser R. "Renal artery aneurysm: success-

- ful exclusion with a stent graft." *Catheter Cardiovasc Interv.* 2004;61:314-6.
7. Wei HB, Qi XL, Liu F, et al. "Robot-assisted laparoscopic reconstructed management of multiple aneurysms in renal artery primary bifurcations: a case report and literature review." *BMC Urol.* 2017 Oct 16;17(1):96. doi: 10.1186/s12894-017-0265-8. Review. Erratum in: *BMC Urol.* 2017 Nov 3;17:100.
 8. Guo H, Wang C, Yang M, et al. "Management of iatrogenic renal arteriovenous fistula and renal arterial pseudoaneurysm by transarterial embolization: A single center analysis and outcomes." *Medicine (Baltimore).* 2017 Oct.
 9. Wei X, Sun Y, Wu Y, et al. "Management of wide-based renal artery aneurysms using noncovered stent-assisted coil embolization." *J Vasc Surg.* 2017 Sep;66(3):850-857. doi: 10.1016/j.jvs.2017.04.035. Epub 2017 Jun. 19.
 10. Nassiri N, Huntress LA. "Stent-Assisted Coil Embolization of a Symptomatic Renal Artery Aneurysm at a Bifurcation Point." *Ann Vasc Surg.* 2017 Jul;42.299.e11-299.e14. doi: 10.1016/j.avsg.2016.10.042. Epub 2017 Mar 7.
 11. Sousa J, Mansilha A. "Endovascular Treatment of Symptomatic Renal Artery Aneurysm with Hostile Anatomy." *Eur J Vasc Endovasc Surg.* 2017 Jun;53(6):843. doi: 10.1016/j.ejvs.2017.02.018. Epub 2017 Mar 17.
 12. Bracale UM, Narese D, Ficarelli I, et al. "Stent-assisted detachable coil embolization of wide-necked renal artery aneurysms." *Diagn Interv Radiol.* 2017 Jan-Feb;23
 13. Adrahtas D, Jasinski P, Koullias G, et al. "Endovascular Treatment of a Complex Renal Artery Aneurysm Using Coils and the Pipeline Embolization Device in a Patient with a Solitary Kidney." *Ann Vasc Surg.* 2016 Oct
 14. Koter SH, Baumann A. "Aneurysm of the Right Renal Artery." *Eur J Vasc Endovasc Surg.* 2016 Jul
 15. Chung R, Touska P, Morgan R, et al. "Endovascular Management of True Renal Arterial Aneurysms: Results from a Single Centre." *Cardiovasc Intervent Radiol* 2016 Jan.
 16. Li G, Sun Y, Song H, et al. "Embolization of ruptured renal artery aneurysms." *Clin Exp Nephrol.* 2015 Oct.
 17. Tsilimparis N, Reeves JG, Dayama A, et al. "Endovascular vs open repair of renal artery aneurysms: outcomes of repair and long-term renalfunction." *J Am Coll Surg.* 2013 Aug.
 18. Sédât J, Chau Y, Baque J. "Endovascular treatment of renal aneurysms: a series of 18 cases." *Eur J Radiol.* 2012 Dec.