

The Effectiveness of Topical Steroid Cream in the Management of Phimosis Developed Following Circumcision Performed With Thermocautery

Termokoterle Yapılan Sünnet Sonrası Gelişen Fimozisin Tedavisinde Topikal Steroid Kremin Etkinliği

Osman Akyüz ¹, Mehmet Nuri Bodakçı ², Zeynep Tatar ³, Müslüm Ergün ¹, Soner Çoban ⁴, Kamil Çam ⁵

1 Medicine Hospital, Department of Urology, Biruni University, Istanbul, Turkey

2 Avcılar Hospital, Department of Urology, Istanbul, Turkey

3 Patomer Pathological Cytological Research Center, Department of Pathology, Istanbul, Turkey

4 Health Sciences University, Bursa Yüksek İhtisas Education and Research Hospital, Department of Urology, Bursa, Turkey

5 Marmara University, Medical Faculty, Department of Urology, Istanbul, Turkey



Geliş tarihi (Submitted): 2020-01-30

Kabul tarihi (Accepted): 2020-05-08

Yazışma / Correspondence

Osman Akyüz

Medicine Hospital, Hoca Ahmet Yesevi
St. No:149 Güneşli, Bağcılar,
Istanbul / Turkey

E mail: akuzosman@hotmail.com

GSM: +90 532 791 94 30

Fax number: +90 212 474 36 94

ORCID

O.A. 0000-0002-1402-7664

M.N.B. 0000-0003-4557-7420

Z.T. 0000-0003-2783-5131

M.E. 0000-0002-7297-5785

S.B. 0000-0002-4687-8754

K.C. 0000-0002-8275-5479



This work is licensed under a [Creative Commons Attribution-NonCommercial 4.0 International License](https://creativecommons.org/licenses/by-nc/4.0/).

Özet

Amaç: Termokoter cihazı, hızlı ve güvenli sünnet için lokal anestezi altında yapılan sünnetlerde ülkemizde yaygın olarak kullanılmaktadır. Termokoterle sünnet sonrası gelişebilecek komplikasyonlardan bir tanesi de patolojik fimozisdir. Ancak literatürde bu komplikasyonun medikal tedavisi ile ilgili çalışma yoktur. Termokoterle sünnet sonrası gelişen patolojik fimozisin tedavisinde topikal kortikosteroid uygulamasının etkinliğini araştırmayı amaçladık.

Gereç ve Yöntemler: 2009 ile 2018 yılları arasında, hastanemizde uygulanan sünnetler sonrası sekonder fimozis gelişen, yaşları 1-8 arasında değişen 68 hastanın verileri bilgisayardan retrospektif incelendi. Termokoter ve bistüri kullanılarak yapılan sünnetlerden sonra gelişen fimozis vakaları iki ayrı gruba ayrılarak topikal steroid tedavisinin etkinliği değerlendirildi.

Bulgular: Termokoterle sünnet sonrası grade 5 fimozis gelişen 32 vaka da steroid tedavisine hiçbir yanıt alınmadı. Grade 4 fimozis gelişen gelişen 16 vakanın üç tanesinde kısmi yanıt alınsa da, bu 48 vakanın tamamına cerrahi düzeltme yapıldı. Bistüri grubunda ise grade 5 fimozis gelişen dört vakada da steroide yanıt alınmazken, grade 4 fimozis gelişen sekiz vakanın dört (%50) tanesinde ve grade 3 fimozis gelişen sekiz vakanın altı (%75) tanesinde steroide yanıt alınarak full retraksiyon sağlandı. Bu grupta toplam on vakaya cerrahi müdahale yapıldı.

Sonuç: Sünnet sonrası gelişen patolojik fimozis durumlarında da topikal steroid kremler kısmen fayda sağlayabilir. Ancak termokoter kullanımını sonrası gelişen yüksek dereceli fimozis vakalarında etkinlik gösterememektedirler.

Abstract

Objective: In our country, thermocautery device is used extensively for circumcision performed under local anesthesia for fast and safe circumcision. One of the complications that may occur after circumcision with thermocautery is pathological phimosis. However, there aren't studies in the literature regarding the medical treatment of pathological phimosis after circumcision with thermocautery. We aimed to investigate the effectiveness of topical corticosteroid application in the treatment of pathological phimosis developed after circumcision with thermocautery.

Material and Methods: Data of 68 patients (aged: 1-8 years) who developed phimosis secondary to circumcisions performed by one surgeon between the years 2009 and 2018 were analysed retrospectively from a computerised database. Cases of phimosis developed after circumcisions performed using thermocautery and scalpel were analysed in two separate groups, and the effectiveness of topical steroid treatment was evaluated.

Results: In the thermocautery group, 32 patients who developed Grade 5 phimosis didn't respond to steroid therapy, while only three of 16 (18.75%) cases with Grade 4 phimosis responded partially to topical steroid treatment. All these 48 cases were treated with surgery. In the scalpel group, no therapeutic response was elicited in four cases who developed Grade 5 phimosis. However, four out of eight (50%) patients with Grade 4 and six out of eight (75%) patients with Grade 3 phimosis responded to steroid therapy, and full retraction of the foreskin was achieved. In the scalpel group, ten cases underwent surgical revision.

Anahtar Kelimeler: Koter, sünnnet, fimozis, topikal steroid

Conclusion: Topical steroid creams may be partially beneficial in cases of pathological phimosis after circumcision. However, they do not show efficacy in cases of high-grade phimosis after thermocautery use.

Keywords: Cautery, circumcision, phimosis, topical steroid

INTRODUCTION

Inability to retract the foreskin behind the glans due to adhesion between the foreskin and the glans is defined as phimosis. It occurs during the neonatal period as a physiological condition in 96% of cases. The incidence of phimosis decreases with age and only 10% of three years old boys have phimosis (1). However, pathological phimosis may develop secondary to chronic infections or circumcision. In recent times, thermocautery has become a popular method of circumcision, especially in children with bleeding diathesis. One of the most frequently seen complications after circumcision is the development of phimosis. In secondary phimosis cases seen after thermocautery circumcision, a very hard fibrotic ring (cicatrix) develops, which entraps the glans penis. Surgical intervention is often required to resolve this problem (2). The risk of a re-operation after circumcision is a serious concern in families. Therefore, they usually want the problem to be eliminated by non-surgical method.

Moreno et al conducted a systematic review of 12 studies. They reported that topical steroid cream application in phimosis could be a safe alternative before surgery (1). The success rates of steroid creams in the treatment of phimosis have been reported in the literature between 65% and 90% (3). In previous studies, it has been reported that topical steroid cream application and stretching methods can be used as an alternative to surgery both in cases with phimosis following circumcision and physiological phimosis. However, phimosis cases reported in these studies were the ones developed after circumcisions performed using methods other than thermocautery (4,5). In the literature, we have not encountered any study that tested the use of steroids in the treatment of phimosis that devel-

oped after thermocautery. In this study, we evaluated the effectiveness of the highly potent steroid clobetasol propionate in the management of secondary phimosis developed after thermocautery or scalpel circumcision.

MATERIAL AND METHODS

A computerised database of patients who developed phimosis secondary to circumcision procedures and who were treated with topical steroid application between the years 2009 and 2018 at our hospital was retrospectively analysed. Patients who developed secondary phimosis after circumcision by thermocautery or scalpel were included in the study. Physiological phimosis patients were not included in the study. A total of 72 childrens whoes families accepted topical steroid cream treatment for secondary phimosis after circumcision with thermocautery. However, three patients in the thermocautery group and one patient in the scalpel group did not continue steroid treatment. These patients were excluded from the study. 68 patients continued to apply steroid cream. Patients with a median age of 3.1 ± 1.1 years (range 1–8 years) were included in the study. All of the circumcisions were performed using the guillotine method in which skin and mucosa are cut simultaneously with thermocautery (n = 48) or scalpel (n=20) (6). Prior to treatment, a physical examination was performed, and phimosis was graded based on the classification system outlined by Kikiros et al. (Grade 0=Full retraction, Grade 1= Full retraction but tight behind glans, Grade 2= partial exposure of glans, Grade 3= Partial retraction but meatus just visible, Grade 4= Slight retraction but neither meatus nor glans can be exposed, Grade 5= Absolutely no retraction) (7). Cases of phimosis developed as a complication of circumcision using thermocautery were Grade 5 (n = 32) and Grade 4 (n = 16). In the scalpel

group (n=20), secondary phimosis was classified as Grade 5 in 4 cases, Grade 4 in 8 cases and Grade 3 in 8 cases. Before initiating treatment, families were offered surgery to revise the circumcision or topical steroid cream application. For six to eight weeks, every morning and night after showering, 0.05% clobetasol propionate (Dermovate 0.05% 50 Gr, Turkey) was applied as a topical cream. The families were informed about possible local and systemic side effects of topical steroids, including thinning of the skin, pigmentations, striae, telangiectasia, hirsutismus and Cushing syndrome, and their formal structured informed consent were obtained. The method used to apply the topical cream after slightly retracting the foreskin was demonstrated to the families. At the end of the application period (6-8 weeks), according to the classification made by Kikiros et al. in cases where complete retraction was achieved (Grades 0, 1 and 2), response to the steroid was considered to be successful. Surgical treatment was applied to patients who did not respond to steroid cream treatment. The sleeve method described for circumci-

sion was modified and the stenotic ring was removed. Our study was approved by the local Ethics Committee regarding Helsinki Declaration and written informed consent was obtained from all participants. (Register No: 2018 / 15-29)

RESULTS

The results we obtained from our study are summarised in Table 1. All patients maintained the treatment for six to eight weeks. None of the 32 (0%) patients with Grade 5 phimosis developed after thermocautery responded to application of 0.05% clobetasol propionate cream. All of these patients underwent circumcision revision surgery (Figures 1 and 2).

Of the 16 cases of Grade 4 phimosis developed after thermocautery, 13 (81.25%) did not respond to therapy, and they underwent surgery. Three of these (18.75%) cases improved to Grade 3. Despite prolonging the treatment for another two weeks, these three cases did not improve further. At control visits one week later, development of Grade 4 phimosis necessitated surgical revision. During postoperative follow-ups, no problems were experienced.

Table 1: Demographic characteristics of the patients and their therapeutic response rates

Number of patients (n)	68
Phimosis developed after use of thermocautery	48
Phimosis developed after scalpel circumcision	20
Age range	1-8 years (3.1 ± 1.1)
Topical steroid cream used	0.05% clobetasole propionate
Duration of application	6-8 weeks
Total number of cases with phimosis in the thermocautery group (n)	48 (0%)
Grade 5 phimosis cases	32 (0%)
Grade 4 phimosis cases	16 (0%)*
Total number of cases with phimosis in the scalpel circumcision group (n)	20 (50%)
Grade 5 phimosis cases	4 (0%)
Grade 4 phimosis cases	8 (50%)
Grade 3 phimosis cases	8 (75%)

*: Partial response was obtained in three cases, and treatment was continued for an additional two weeks. However, in these cases Grade 4 phimosis still developed.

⊘: Partial response was obtained in two cases, and treatment was continued for an additional two weeks. However two patients still developed Grade 3 phimosis.

#: Values within parentheses demonstrate response rates to treatment

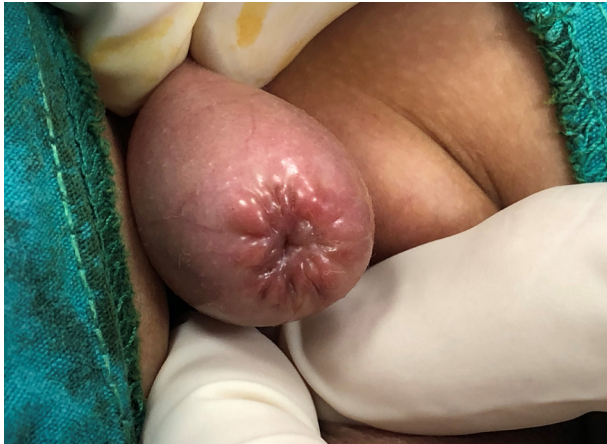

Figure 1. Grade 5 phimosis developed following thermocautery circumcision

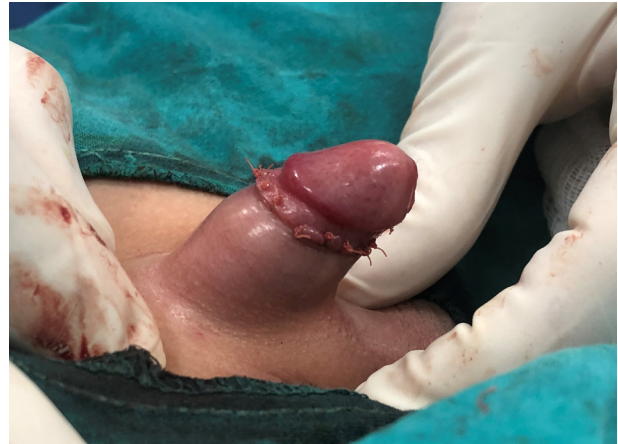

Figure 2. Appearance of the penis in figure 1 after surgical revision

In the four patients who developed Grade 5 phimosis after scalpel circumcision, steroid treatment did not elicit any response (0%), so surgical revision was performed. In the eight cases of Grade 4 phimosis, four responded (50%) to steroid treatment. After treatment, one of these (25%) cases improved to Grade 0, and three cases (75%) to Grade 1. Surgical revision was performed for four patients (50%) who did not improve. Six of the eight (75%) patients with Grade 3 phimosis treated with topical steroid application improved to Grade 0 after six weeks of therapy. In two of these (25%) patients whose phimosis improved to Grade 2, treatment was prolonged for an additional two weeks. At a control visit one month later, their phimosis has worsened to Grade 3, which required surgical intervention. Steroid-related side effects were not observed in any case.

DISCUSSION

Circumcision is one of the most frequently performed surgical interventions, and its application dates back to ancient times (8). Therefore, many surgical techniques and equipment have been designed for circumcision. Various complications have been observed depending on the equipment and technique used. Simple complications, such as bleeding, can develop, while critical complications such as secondary phimosis, which might require surgical re-intervention, may be seen. Krill et al reported secondary phimosis requiring reoperation in 2% of cases after circumci-

sion (9). In a recent study, the plastibell technique was compared with the conventional method. The rate of development of secondary phimosis was found to be 2.4% in the conventional method which was reported to be statistically significant (10). A new generation of devices using thermocautery to perform circumcision is commonly used in developing countries. Akyüz et al reported that one of the most frequently developed complications after circumcisions performed using thermocautery was secondary phimosis. In the same study, incidence of secondary phimosis related to thermocautery was reported to be 0.38 percent (2).

In recent years, topical steroid creams have been used in the treatment of phimosis due to their low cost, side effects and ease of administration. As is the case with congenital phimosis, topical steroids can be used as a course of treatment before surgical correction of secondary phimosis. We informed the families in this study about surgical treatment, medical therapy with topical steroids, and the success rates of these treatments. The penile retraction with steroid cream is self-treatment modality. Therefore, compliance with the treatment and motivation of parents is very important. The cases in our study were children who had undergone circumcision under local anesthesia during circumcision campaigns, who had experienced psychological trauma as a result. All of the families preferred topical steroid treatment in the hope of avoiding surgical re-intervention.

Two mechanisms have been reported for steroid creams used in the treatment of phimosis. It is thought that their anti-inflammatory and immunosuppressive actions block the formation of prostaglandin and leukotriene precursors from mediators that play a role in cutaneous inflammation. Importantly, they inhibit the synthesis of glycosaminoglycans, especially hyaluronic acid and collagen, from fibroblasts with subsequent thinning of the skin (11). Topical steroid application has local and systemic side effects, mainly skin atrophy. Systemic adverse effects of topical corticosteroid on the foreskin in cases of phimosis on the hypothalamic-pituitary-adrenal axis have not been reported (12). Golubovic et al. could not detect any difference in morning cortisol levels between individuals treated with betamethasone and control groups (13). In our study, we did not encounter any local or systemic side effects of topical steroid therapy. As indicated in many studies in infants aged less than six months, topical steroids have a high penetration, and the use of very potent topical steroids should be avoided (14). In our study group, the youngest patient was one year old.

The most efficient use of topical corticosteroids is still under debate. A few studies related to their use in phimosis suggest that use of topical steroids for four weeks is safe and effective (15,16). Esposito et al. reported that in congenital phimosis, topical steroid application has success rates ranging between 65 and 95% and indicated that this method is a safe and economical alternative to surgery (17). Even though the

effectiveness of topical steroids has been demonstrated in many studies, the best topical steroid agent and application protocol have not yet been defined. Lee et al. reported a 68% success rate with 0.05% clobetasol propionate cream. They indicated that this procedure is a safe, simple and effective method without any significant side effects in prepubertal children with severe phimosis (18). In another study, Kiss et al. applied mometasone furoate in the treatment of pathological phimosis due to balanitis xerotica obliterans in children. All patients underwent surgical intervention because phimosis was not treated (19). In a similar study, Makhija and colleagues applied mometasone cream in non-retractable prepuce and reported a success rate of 84% (20). Similarly, Favorito et al. reported that they received 85% response to betamethasone cream (0.2%) + hyaluronidase treatment in physiological phimosis. When they applied circumcision to the cases that did not respond to treatment, examined histopathologically, they determined that elastic fibers decreased, and type III collagen increased (21).

We also preferred to use highly potent steroids for topical treatment. Fibrotic rings encountered in phimotic cases developed after circumcisions performed with thermocautery were harder than those formed in cases of congenital phimosis. The pathological examination of the surgically excised scar tissue which did not respond to steroid treatment, showed hypertrophic scar tissue formed by hypocellular thick and coarse collagen bundles and dense inflammation (Figure 3).

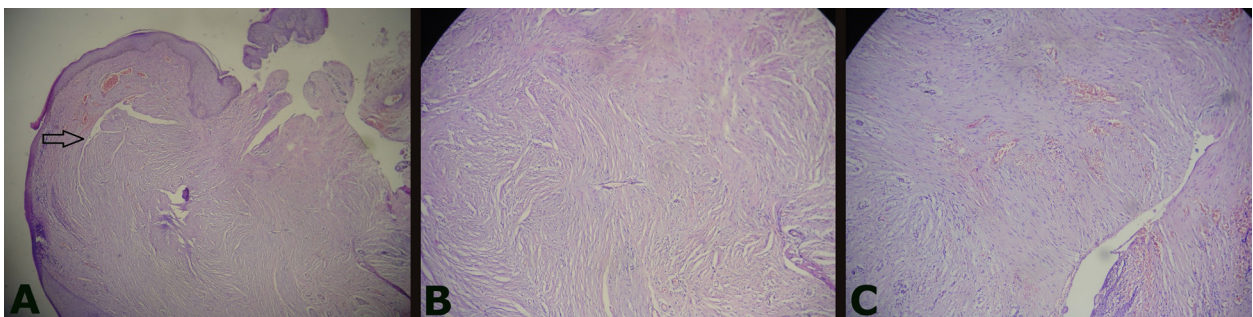


Figure 3. Illustrations of routine sections prepared with hematoxylin - eosin staining are shown in this figure. Hypertrophic scar tissue proliferating, leaving a narrow lesion-free zone beneath the overlying superficial squamous epithelium is seen. This scar tissue is composed of thick coarse relatively hypocellular collagen bundles when compared with surrounding tissues. The presence of interspersed congested blood vessels and mixed inflammation is seen (3A- Arrow).

We considered that in these cases of phimosis, topical steroids with a lower potency may be less effective, so we used topical steroids with a higher potency. Though a partial response was obtained in three cases, we could not elicit any long-term response to therapy in the thermocautery group, so we had to perform surgery for all patients. In cases of phimosis that developed secondary to scalpel circumcision, we obtained a lower response rate (50%) similar to that achieved in previous studies.

As to the limitations of the study, the penile retraction with steroid cream is self-treatment modality. Motivation and sensitivity of the parents in the application of steroid cream is important.

CONCLUSION

We think that the use of topical steroid creams is not beneficial in children whose circumcision was performed using thermocautery and who developed Grade 4 and 5 scars secondary to circumcision. In our cases, when circumcision had initially been performed under local anesthesia, application of topical steroid therapy was psychologically traumatic for children and their parents. If thermocautery is used for circumcision, then a firmer fibrotic ring is formed, so cases with higher grades of phimosis are encountered. Though it is useful in some cases of congenital phimosis, unfortunately topical steroids are almost useless in these secondary cases. In cases of high grade phimosis developed after the use of thermocautery, we think that direct surgical revision without spending time on medical treatment is a more appropriate approach.

Financial support and sponsorship: Nil.

Conflicts of interest: There are no conflicts of interest.

Ethical approval: Our study was approved by the local Ethics Committee regarding Helsinki Declaration and written informed consent was obtained from all participants. (Register No: 2018 / 15-29).

REFERENCES

1. Moreno G, Corbalán J, Peñaloza B, Pantoja T. Topical corticosteroids for treating phimosis in boys. *Cochrane Database of Systematic Reviews* 2014, Issue 9. Art. No: CD008973. DOI: 10.1002/14651858.CD008973.pub2.
2. Akyüz O, Bodakçı MN, Tefekli AH, Thermal cautery-assisted circumcision and principles of its use to decrease complication rates. *J Pediatr Urol* 2019;19. pii: S1477-5131(19)30005-1.
3. Nascimento FJ, Pereira RF, Silva JL, Tavares A, Pompeo AC. Topical Betamethasone and Hyaluronidase in the Treatment of Phimosis in Boys: a Double-Blind, Randomized, Placebo controlled Trial. *Int Braz J Urol* 2011;37:314-319.
4. Zampieri N, Corroppo M, Camoglio FS, Giacomello L, Ottolenghi A. Phimosis: stretching methods with or without application of topical steroids? *J Pediatr* 2005;147:705-6.
5. Alpert SA, Ching CB, DaJusta DG, McLeod DJ, Fuchs ME, Jayanthi VR. Combination treatment for cicatrix after neonatal circumcision. An Office based solution to a challenging problem. *J Pediatr Urol* 2018;14: 471-475.
6. Abdulwahab-Ahmed A, Mungadi IA. Techniques of Male Circumcision. *J Surg Tech Case Rep* 2013;5:1-7.
7. Kikiros CS, Beasley SW, Woodward AA. The response of phimosis to local steroid application. *Pediatr Surg Int* 1993;8:329-32.
8. Dunsmuir WD, Gordon EM. The History of Circumcision. *BJU International* 1999; 83:1-12.
9. Krill AJ, Palmer LS, Palmer JS. Complications of circumcision. *Scientific World Journal* 2011;11:2458-68.
10. Talini C, Antunes LA, Carvalho BC, et al. Circumcision: postoperative complications that required reoperation. *Einstein São Paulo* 2018;16:1-5.
11. Shahid SK. Phimosis in children. *ISRN Urol* 2012;4:32-39.
12. Balamtekin N, Uluocak N, Atay A, Aydın HI, Karabıyık I. The effect of topical corticosteroid creams on phimosis treatment. *Erciyes Medical Journal* 2006;28:120-24.
13. Golubovic Z, Milanovic D, Vukadinovic V, Rakic I, Perovic S. The conservative treatment of phimosis in boys. *Brit J Urol* 1996;78:786-88.
14. Findling JW, Doppman JL. Biochemical and radiologic diagnosis of Cushing's syndrome. *Endocrinol Metab Clin North Am* 1994;23:511-37.
15. Ashfield JE, Nickel KR, Siemens DR, Macneily AE, Nickel JC. Treatment of phimosis with topical steroids in 194 children. *J Urol* 2003;169:1106-08.
16. Kuehhas FE, Miernik A, Sevcenco S, Tosev G, Weibl P, Schoenthaler M, Lassmann J. Predictive power of objectivation of phimosis grade on outcomes of topical 0.1% betamethasone treatment of phimosis. *Urology* 2012;80:412-16.

17. Esposito C, Centonze A, Alicchio F, Savanelli A, Settimi A. Topical Steroid Application versus Circumcision in Pediatric Patients with Phimosis: A Prospective Randomized Placebo Controlled Clinical Trial. *World Journal of Urology* 2008;26:187–90.
18. Lee CH, Lee SD. Effect of topical steroid (0.05% clobetasol propionate) treatment in children with severe phimosis. *Korean J Urol* 2013;54:624–30.
19. Kiss A, Csontai A, Pirót L, Nyirády P, Merksz M, Király L. The response of balanitis xerotica obliterans to local steroid application compared with placebo in children. *J Urol* 2001;165:219-20.
20. Makhija D, Shah H, Tiwari C, Dwiwedi P, Gandhi S. Outcome of topical steroid application in children with non-retractile prepuce. *Dev period med* 2018;22,1:71-4.
21. Favorito LA, Balassiano CM, Rosado JP, Cardoso LEM, Costa WS, Sampaio FJB. Structural analysis of the phimotic prepuce in patients with failed topical treatment compared with untreated phimosis. *Int Braz J Urol* 2012;38:802-8.